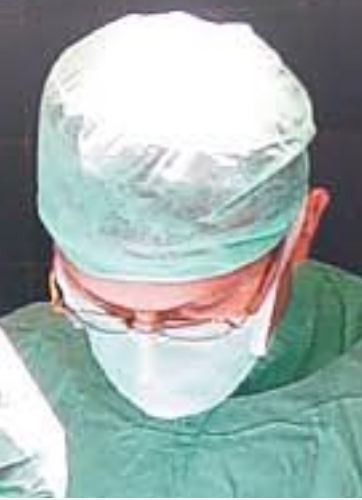



ROYAL AUSTRALASIAN COLLEGE OF SURGEONS



LESSONS FROM THE AUDIT

This booklet has been produced with examples of significant cases from QASM, where there may have been 'a lesson to be learned', with comments by first and second line assessors.

This booklet is issued to all Trainees and Fellows of the College.

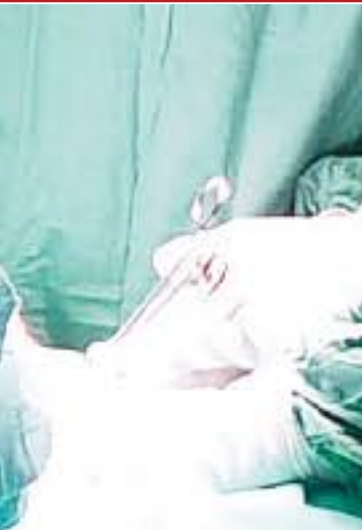Cases are from
October 2007 – April 2008


NOT TO BE DISTRIBUTED

Copyright Royal Australian College of Surgeons
Supported by Queensland Health

QASM

Queensland Audit of Surgical Mortality





Anastomotic Leaks

CASE 1

Summary

A 66 year old female presented with a stenosing carcinoma of the left colon identified on colonoscopy. The patient was morbidly obese, diabetic, on steroids, and classified ASA 4 (incapacitating systemic disease that is a constant threat to life).

A wedge resection of the tumour of the descending colon was performed with primary anastomosis. In spite of an apparently uneventful immediate post-operative course there was sudden, general, and cardio respiratory deterioration on day 5 necessitating a laparotomy and stoma formation for an anastomotic leak. A left subphrenic abscess subsequently developed requiring CT drainage on day 30 and thereafter general deterioration occurred resulting in death.

Comment

The morbid obesity and the steroid dependence in this patient made diagnosis of anastomotic leak difficult in the post-operative period. The patient was apparently well, afebrile with a normal white cell count and no physical findings for the first few days. The surgeon considered that obesity and the steroid dependency masked early signs.

CASE 2

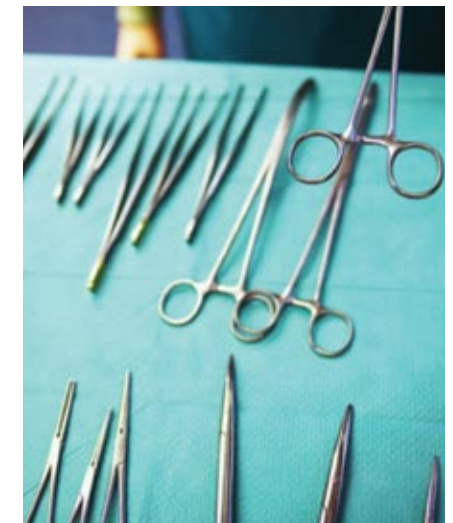
Summary

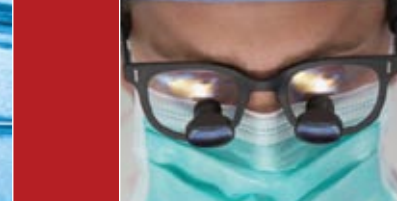
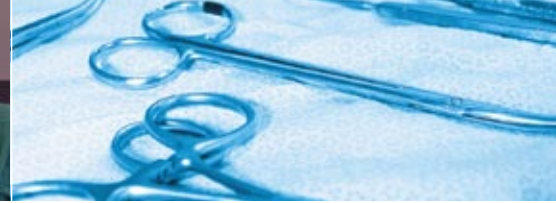
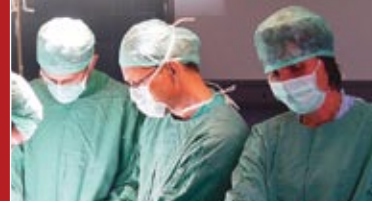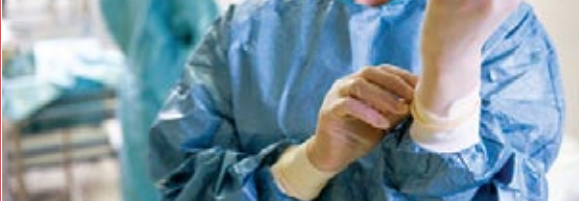A 62 year old male was admitted to a urology ward with pneumaturia and a subsequent diagnosis was made of colovesical fistula due to diverticular disease. A one-stage resection was performed but the surgeon describes

difficulty with the anastomosis which had to be redone because of "anastomotic ischemia". In spite of this, the anastomosis was not covered. On day 4 an anastomotic leak was diagnosed with deterioration in the patient's condition and return to OT. On this occasion a subtotal colectomy and end- ileostomy was performed because of ischemia of the colon, and at this time, a frankly cirrhotic liver was noted (not appreciated pre-operatively). The patient's condition deteriorated post-operatively with liver failure and gradual deterioration culminating in death one month later.

Comment

The surgeon notes that in the light of intra-operative difficulties with the original anastomosis, a covering stoma or perhaps a Hartmann's procedure would have been preferable and the degree of liver impairment had not been appreciated pre-operatively.





CASE 3

Summary

A 66 year old male presented with generalised peritonitis, free gas under the diaphragm and was intoxicated. The patient was taking Plavix. At laparotomy, a perforated caecum was found due to an obstructing ascending colon cancer, and a right hemicolectomy with primary anastomosis was performed. A second-look laparotomy was performed 48 hours later for evacuation of clot, and the anastomosis appeared to be intact.

On day 10 a tracheostomy was required and an anastomotic leak with faecal peritonitis was diagnosed that day. A further laparotomy with end-ileostomy and mucous fistula was performed. A separate abscess in the left subphrenic space was drained. Three days later a laparotomy was again necessary because of intra-peritoneal bleeding and splenectomy required for haemorrhage from the splenic capsule. Soon after this rapid deterioration occurred, culminating in death.

Comment

In addition to being on Plavix this patient had coronary artery disease and chronic obstructive pulmonary disease (COPD). The surgeon has made the point that primary anastomosis under these circumstances, in the presence of sepsis, may have been unwise and that ileostomy and a mucous fistula may have been the wiser course in this case.

CASE 4

Summary

A 71 year old female presented with a large bowel obstruction thought to be due to a carcinoma of the splenic flexure. She had a

right mastectomy ten years previous which was followed by chemotherapy for carcinoma of the breast.

Laparotomy was performed the same day and extensive peritoneal seedings found, particularly in the region of the splenic flexure where there was some obstruction. A subtotal colectomy and ileosigmoid anastomosis was performed and the subsequent histology indicated metastatic breast cancer and not a primary colonic tumour. Her immediate post-operative course was satisfactory but on the 9th post-operative day she collapsed with generalised deterioration and a diagnosis of peritonitis due to an anastomotic leak was made. Because of the extensive carcinomatosis and after discussion with the family no further treatment was given.

Comment

Resection with anastomosis in the presence of extensive peritoneal metastases carries a higher leak rate and higher mortality rate and a bypass procedure under these circumstances would also have obviated the need for a stoma and possibly provided a more conservative palliative procedure.

CASE 5

Summary

A 70 year old female presented with a strangulated left femoral hernia and repair undertaken with resection of small bowel. This anastomosis is described as “standard, stapled, functional end-to-end” with a supporting “trouser crutch” suture. On day 6 the patient required laparotomy for an anastomotic leak and a small contained leak found at the point of the “trouser crutch” suture. A second anastomosis after resection

of this was a “double layered, hand-sutured, side-to-side” anastomosis.

Comment

The surgeon made the point that a different anastomotic technique (hand sutured as opposed to stapled) may not have leaked.

CASE 6

Summary

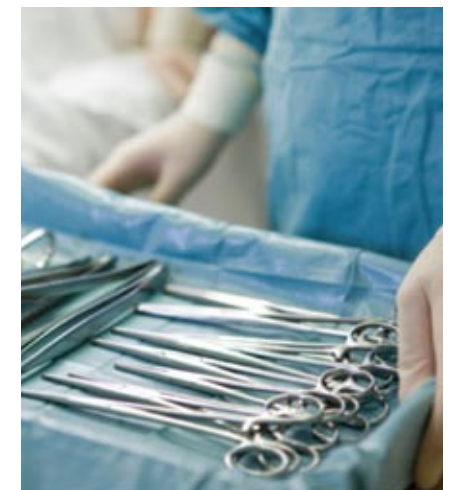
An 80 year old female patient with chronic stable ischaemic cardiomyopathy was transferred to a base hospital on a Friday evening. She gave a history of 6 months of weight loss with recent vomiting and abdominal distention. A diagnosis was made of a large bowel obstruction. The following day, a CT scan of her abdomen showed a stricture in the mid-ileum and the following day laparotomy was performed. A carcinomic tumour of the ileum was found with evidence of nodal metastasis and resection with primary anastomosis was performed using two layers of continuous chromic catgut. The surgical notes refer to an obvious discrepancy in the bowel lumen diameter.

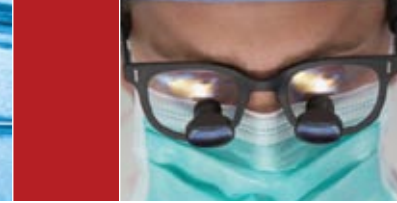
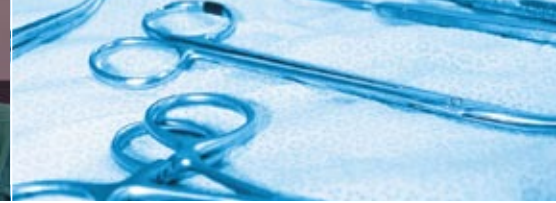
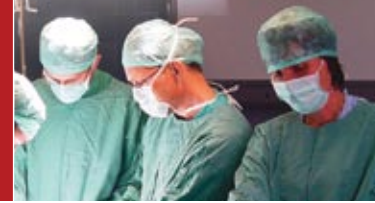The patient's immediate post-operative course was relatively straight forward but on day 5 her condition deteriorated with hypotension, oedema, atrial fibrillation, pleural effusions, and hypoalbuminaemia. The patient was transferred to the ICU where a CT scan was performed on day 6 confirming an anastomotic leak. Laparotomy was performed the following day by a different surgeon and a re-resection with stapled anastomosis was performed and washout of the peritoneal cavity. In the post-operative period her condition generally deteriorated and the patient expressed desire for supportive treatment only and died about 10 days later.

Comment

1. The anastomotic technique at the first operation was not standard and an end-to-end anastomosis in a chronic small bowel obstruction with gross discrepancy in lumen size will carry with it a higher risk of anastomotic leak.
2. Post-operative fluid balance in the immediate post-operative period was less than satisfactory with grossly positive fluid balance (in excess of 3 litres) on two consecutive days.
3. The patient was still receiving anti-hypertensive medication when hypotensive in the post-operative period.
4. Having diagnosed an anastomotic leak, the second laparotomy was performed more than 24 hours later.

Although this frail elderly patient had significant co-morbidities there were several issues in management identified.





Aspiration of Vomitus

CASE 1

Summary

A 70 year old female presented with an adhesive small bowel obstruction having had more than 30 previous laparotomies and was taking methadone 130mg daily for chronic back pain. She had a permanent stoma. A Gastrograffin follow through was ordered and the surgeon and the registrar went to the Radiology department to check the results to find the patient unresponsive (and unmonitored). After resuscitation the patient was transferred to ICU. A chest x-ray revealed that Gastrograffin had been aspirated and the patient's condition deteriorated in the intensive care ward and she died two days later.

Comment

Gastrograffin is extremely irritant in the lungs and the risk of inhalation is significant. These patients should be monitored carefully if this investigation is requested.

CASE 2

Summary

A 73 year old male presented with anaemia and weight loss and a carcinoma of the ascending colon diagnosed on the basis of CT scan. Attempting to confirm this, a colonoscopy was ordered and bowel preparation for this begun. Overnight the patient aspirated fluid and was then transferred to a respiratory HDU to treat this aspiration. The patient's condition slowly improved but after two weeks suffered a tension pneumothorax followed by a cardiac arrest from which she did not recover.

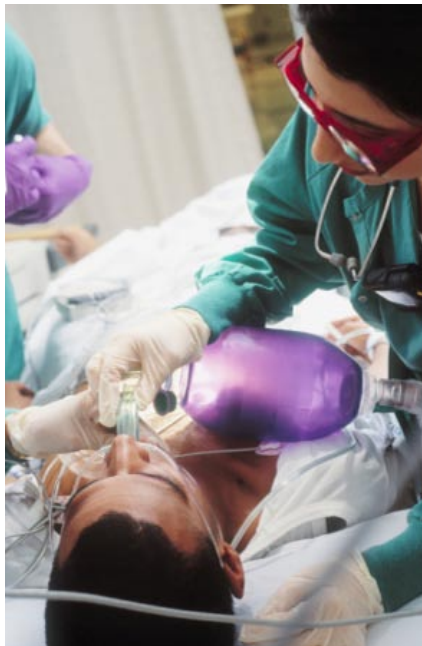Comment

Whilst bowel preparation is necessary prior to colonoscopy, surgery could probably have proceeded in this case without the need for endoscopic confirmation.

CASE 3

Summary

A 79 year old male was admitted for a Hartmann's hook-up having previously had a Hartmann's procedure for diverticulitis. An incidental finding in the pathology at the initial operation was a small carcinoma (ACPS-A) but the primary pathology was perforated diverticular disease. The hook-up was prolonged with anaesthesia time recorded at five hours and in the post-operative period the patient complained of



nausea and vomiting. On the second post-operative day a succussion splash was evident clinically but in spite of this, oral fluids were encouraged. Nausea and vomiting persisted over the next 24 hours and a nasogastric tube was inserted. By this time the patient had already vomited and inhaled, and soon after sustained a cardiac arrest from which he could not be resuscitated.

Comment

The patient complained of feeling unwell, nausea, and was vomiting and should have had a nasogastric tube inserted with restriction of oral intake some 36 hours prior to his demise.

CASE 4

Summary

A 68 year old male was admitted for elective laparoscopic right hemicolectomy for a tumour in the right colon. The procedure was uncomplicated and the operating time was under two hours. The unit has an early-feeding policy and on day 2 the patient vomited and aspirated producing severe respiratory distress and was transferred to the intensive care unit and put on a respirator. Because of severe brain injury consequent to this, active treatment was withdrawn and the patient died 11 days later.

Comment

The early-feeding policy may have contributed to vomiting and hence aspiration.

Arterial embolisation to prevent bleeding

CASE 1

Summary

A 73 year old male admitted with hematemesis was initially diagnosed as aorto-duodenal fistula. Laparotomy and exploration of the aorta was performed but no source of bleeding found. Angiogram the next day diagnosed a fistula between an hepatic artery aneurysm and the gall bladder. This was embolised resulting in progressive hepatic failure and death.

Comment

Although embolisation of the hepatic artery aneurysm was thought necessary to stop bleeding, it produced a fatal result in progressive hepatic failure.

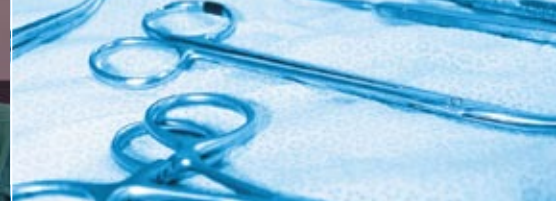
CASE 2

Summary

A 56 year old female who had undergone a liver transplant presented with subarachnoid haemorrhage (grade 5). The cause of the subarachnoid haemorrhage was a posterior cerebral artery aneurysm and this was treated by endovascular coiling resulting in brain infarction in the posterior cerebral artery territory and death.

Comment

Although endovascular coiling was necessary to prevent bleeding from the posterior cerebral artery aneurysm, it produced a fatal result infarcting the brain in the posterior cerebral artery territory.

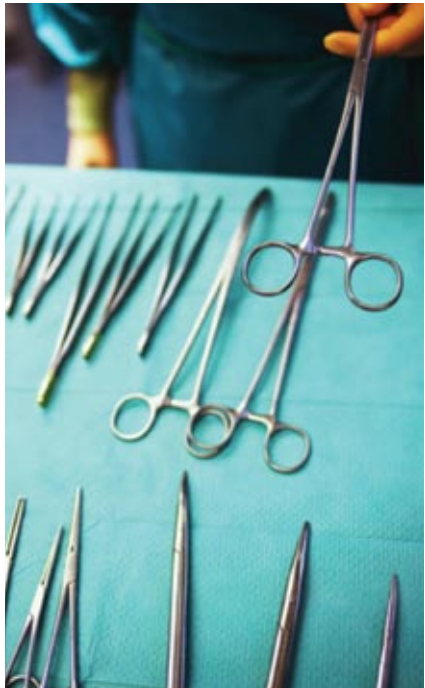


Gallstone Pancreatitis

CASE 1

Summary

A 69 year old female admitted with gallstone pancreatitis on a background of chronic renal failure, reno-vascular hypertension, ischemic heart disease, prior CVAs, hypothyroidism. Early ERCP was discussed with gastroenterology but the advice was to wait. The next day the patient developed severe chest pain due to myocardial infarct and was transferred to coronary care ward and anti-coagulated. There was general deterioration in cardiac and metabolic state. No further treatment was offered after discussion with the family.



Comment

Earlier ERCP may have altered the clinical course of this case but after discussion with the gastroenterologist it was decided to wait. The myocardial infarct the following day was responsible for deterioration and ultimately death.

Misadventure ICU

CASE 1

Summary

An 82 year old female presented with a carcinoma of the transverse colon and a lap assisted extended right hemicolectomy performed. The immediate post-operative course was described as "reasonable". On day 8 she developed generalised abdominal pain and was thought to have an ileus. TPN was instituted. A CT of the abdomen showed pelvic fluid and free air on day 13 and on day 15 a laparotomy was performed but no anastomotic leak found. Infected haematoma was evacuated from the pelvis. She was admitted to the intensive care ward where on day 28 she sustained a fall fracturing her left femur and thereafter deteriorated with sepsis and positive blood cultures and died on day 32.

Comment

The misadventure in the ICU was a fall producing a fractured left femur which seemed to be the final insult in a deteriorating clinical course.

Cardiac

CASE 1

Summary

A 78 year old male underwent elective Mitral Valve Repair. The initial repair was not satisfactory and a second period of aortic cross clamping was required to redo the repair producing a prolonged total bypass time of 154 minutes. Final intra-operative assessment of the repair was satisfactory. The patient was slow to wake up and was noted twelve hours post-operatively to have left-sided weakness and a CT scan showed an embolic left middle artery stroke. This occurred on a Friday afternoon and he was discharged from the intensive care unit to the ward. In the early hours of the following morning his observations were unstable with increasing respiratory rate, low blood pressure and oxygen saturations and poor urine output. He developed atrial fibrillation. He was readmitted to the Intensive Care Unit where an echocardiogram showed a pericardial effusion, and he was then acidotic with atrial fibrillation. It was thought necessary to exclude ischemic bowel so laparoscopy was performed but this was normal and because of ongoing instability he was returned to theatre where a large tamponade was drained. From this point the patient developed progressive multiple organ dysfunction resulting in death on the 4th day after the second operation, 8 days after the first procedure.

Comment

1. The discharge of an unwell patient to the ward on a Friday afternoon may have been unwise. Ongoing assessment in an HDU would have picked up the problem earlier.

2. A transoesophageal echo should have been done.
3. There may have been enough evidence to return the patient to the operating theatre 12 hours earlier but it is not certain if this would have made a difference.

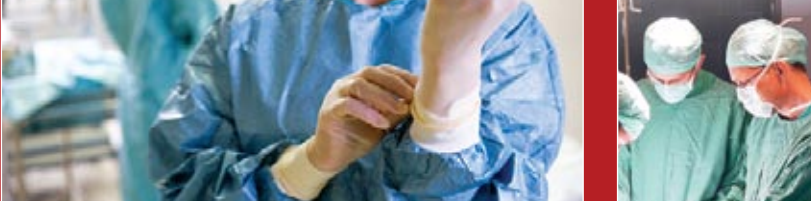CASE 2

Summary

A 70 year old lady presented with a recent myocardial infarction. Investigation revealed severe left main stem critical right coronary ostial disease with anterior descending and circumflex disease and preserved ventricular function. Internal mammary grafting to the anterior descending coronary and vein grafting to circumflex and right coronary territories was performed. The operative procedure was uneventful. Several hours after return from theatre, cardiac arrest occurred associated with significant blood loss and during resuscitative effort the chest was opened. The site of bleeding was a side branch on a vein graft which was corrected after urgent reopening in a life threatening situation in the Intensive Care Unit. Poor cardiac function, despite maximum resuscitative efforts, resulted in the unanticipated demise of the patient.

Comment

The misadventure was clearly associated with the opening of the vein graft side branch. The assessor recommended a Root Cause Analysis as an educational tool for Trainees to be made aware of the importance of careful application of closure devices to vein side branches.



Excessive Analgesia in undiagnosed acute abdomen

CASE 1

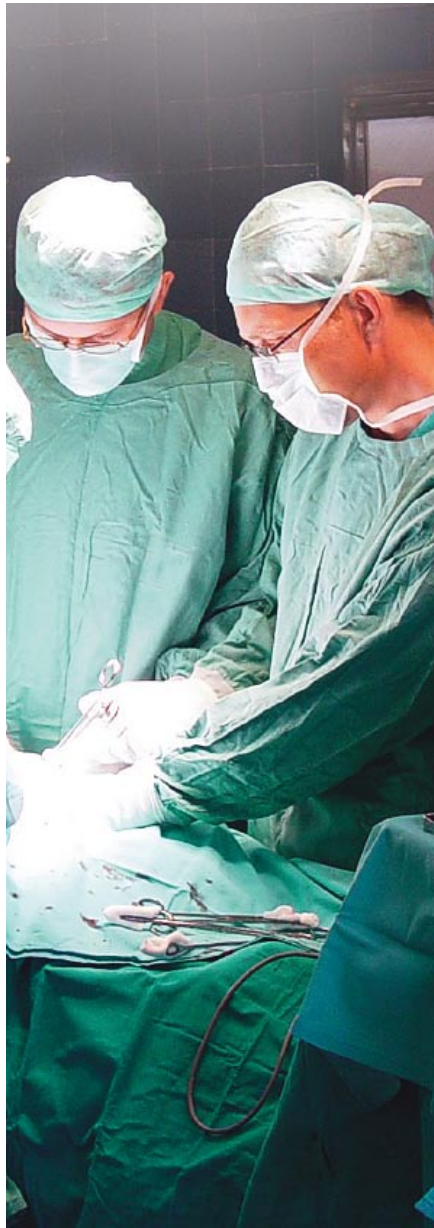Summary

A 75 year old female with chronic renal failure was admitted from dialysis complaining of abdominal pain and vomiting. She had a colostomy in place. Her abdomen was tender and an abdominal CT scan indicated small bowel distention and oedema of the mesentery. She was treated conservatively and when the IV drip tissue fluids were given subcutaneously and no effort was made to use the fistula under these circumstances. During this time of conservative treatment a total of nine doses of Morphine (5mg) were given and the patient was found dead 32 hours after admission.

Comment

1. This patient should have been admitted to a combined renal/surgical unit.
2. A wider differential diagnosis should be considered in patient requiring repeated analgesia – particularly ischaemic bowel, pancreatitis or closed loop obstruction.
3. Given the narcotic requirement, consideration for laparotomy should have been formally and explicitly documented. Alternate narcotic analgesic (Fentanyl) should have been used and Narcan should have been considered in resuscitation.

Combined renal and surgical admission primarily to a centre for definitive care may have changed the outcome.





Queensland Audit of Surgical Mortality



ROYAL AUSTRALASIAN
COLLEGE OF SURGEONS

PO Box 79 Spring Hill QLD 4004
Telephone: (07) 3835 8671 Fax: (07) 3236 9320
Email: qasm@surgeons.org Web: www.surgeons.org