



ROYAL AUSTRALASIAN  
COLLEGE OF SURGEONS

**QASM**

Queensland Audit of Surgical Mortality



Northern Territory Audit  
of Surgical Mortality

DECEMBER 2011

# LESSONS from the AUDIT **VOLUME 8**

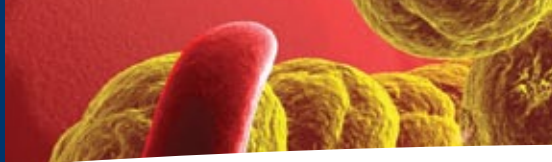


Northern  
Territory  
Government

Copyright Royal Australasian College of Surgeons



Queensland Government  
Queensland Health



## Introduction

---

### 100 lessons – what have we learnt?

*Lessons from the Audit* (Volume 8) is a milestone publication for the Queensland and Northern Territory Audits of Surgical Mortality. It brings to you and your peers our 100<sup>th</sup> case study since our first volume in 2008. Thank you for making this possible. We would never have achieved such a milestone without your participation in the Audits.

I trust all 100 case studies presented to date have been useful reading and highlighted to you the importance of peer review and audit. I trust that the next 100 case studies will be as interesting and as informative for all Queensland and Northern Territory surgeons in their patient care practices.

I must acknowledge Dr Jon Cohen, QASM Clinical Director 2007-2009, who was instrumental in initiating and reviewing *Lessons from the Audit* (Volume 1 to 4).

The Audit staff also deserves special thanks for their efforts in bringing you a reader-friendly publication.

To all my colleagues, I sincerely value your input and support of our mortality audit processes.

Many thanks.

John North

Clinical Director

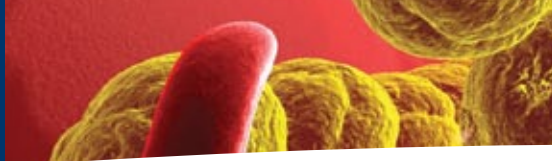


## Contents

---

1. Always treat the patient, rather than the investigation.	2
2. Junior surgeons need experienced surgical supervision.	4
3. When standard care is refused.	6
4. High speed: high mortality!	7
5. Remote-location decision making.	9
6. A simple case of sore elbow?	11
7. Death after endoscopy – ‘surgical audit’ or not?	12
8. Complex cases call for close collaboration.	13

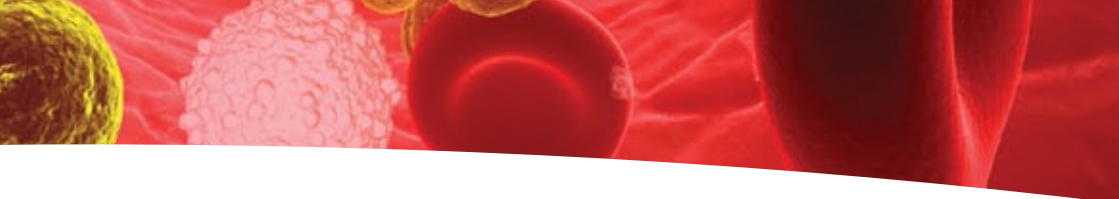
DISCLAIMER: This booklet is produced for Fellows of the Royal Australasian College of Surgeons. Information is obtained under a quality assurance activity. Detail that may identify individuals has been changed, although the clinical scenarios are based on real cases.



## Abbreviations

---

BP	blood pressure
CRP	C-reactive protein
CT	computed tomography
CCU	coronary care unit
CPR	cardiopulmonary resuscitation
C6/7	cervical spinal level
ED	emergency department
ESR	erythrocyte sedimentation rate (mm/hr)
ESWL	extracorporeal shockwave lithotripsy
FAST	focused abdominal sonography in trauma
FFP	fresh frozen plasma
GP	general practitioner
ICU	intensive care unit
IDC	indwelling catheter
INR	international normalised ratio
IV	intravenous
IVT	intravenous therapy
NBM	nil by mouth
NTASM	Northern Territory Audit of Surgical Mortality
QASM	Queensland Audit of Surgical Mortality
RUQ	right upper quadrant
WCC	white cell count



## 1. Always treat the patient, rather than the investigation.

---

An elderly patient with multiple medical co-morbidities was admitted to a local hospital with initial symptoms of severe rapid onset epigastric and RUQ pain with radiation to the back.

No signs of peritonism were elicited. Investigations identified a neutrophil leukocytosis; tachypnoea and tachycardia were also noted. The pain was partially controlled with narcotics.

Differential diagnoses included possible dissection of a major vessel or gut ischaemia. CT was non-diagnostic, but it was noted that there was a dilated gallbladder. There were no additional radiological signs of concern. Given the patient's deterioration and undiagnosed pain, transfer to a major hospital was arranged.

Over the next few days, the patient's pain persisted; there was an increase in the total WCC and a progressive shift to the left. Renal function slowly deteriorated. Lactate was normal. CRP and ESR were not requested.

Repeat CT did not provide any additional diagnostic information.

Fluid balance data was scant. Both input and output data was incomplete.

Both replacement and output were less than optimal.

On arrival at the major hospital, the patient was septic and dehydrated, and there was a clinical suspicion of peritonitis.

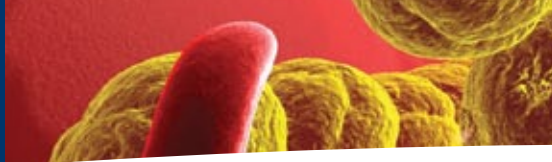
Resuscitation was followed by laparotomy and a tortured and necrotic gallbladder was discovered. Subsequent course was complex.

### Comment:

In retrospect, the outcome would probably have been better with earlier identification of the significant intraperitoneal pathology, more appropriate fluid management and earlier transfer to a large hospital.

A relatively 'normal' CT may, in the absence of definitive clinical or other data, have provided understandable support (albeit deceptive) for further conservative management.

Fluid management, from both medical and nursing perspectives could have been better. A urinary catheter would have simplified output data collection and should have been considered much earlier. Data documentation was poor. Fluid replacement was seriously hampered by the absence of basic data.



Ongoing pain with an increasing WCC and decreasing renal function should have raised more concern and prompted earlier discussion with the major hospital. The use of inflammatory markers such as CRP would have been useful in evaluation and progressive monitoring of the abdominal symptoms.

Sudden severe onset of abdominal pain, in the elderly, which is not relieved by narcotics, should immediately raise the spectre of visceral perforation or an ischaemic process – in this particular case sepsis and gallbladder ischaemia (note the dilated gallbladder on CT).

**In these circumstances, timelines should be established in respect of resuscitation and exploration before the systemic complications of the process become irreversible.** For instance, pain following admission, unrelieved and prolonged (for more the six hours) requires urgent arrangements for exploration. Once a timeline is established at initial assessment, it should be strictly adhered to.





## 2. Junior surgical trainees need experienced surgical supervision.

---

A middle-aged morbidly obese (140kg) patient with Type II diabetes mellitus, hypercholesterolaemia and hypertension, presented to a regional hospital with two weeks of abdominal pain which had briefly improved on antibiotics.

(Dietary restraints were not evident and there had been previous surgery for an abdominal injury.)

The previous week the patient was seen at the local hospital and an Xray showed distended small bowel loops in the pelvis.

On the day before admission to the regional hospital, the patient's GP arranged a CT scan which commented on an 'enlarged appendix with an associated small pocket of fluid in the right iliac fossa. The appearance would be consistent with acute appendicitis'.

On the day of admission to the regional hospital, the patient was admitted to the ward by mid-afternoon. The patient was fasted, commenced on IV fluids and given appropriate antibiotics with a plan for surgery that evening. The surgery was postponed in favour of other category 'A' cases. The patient was allowed to eat and drink (NBM from midnight). Fluid balance chart recorded output as 'no measure, and one litre normal saline in progress'.

Laparoscopy (the following morning) revealed what the CT had shown, with

'difficult anatomy' and the 'appendix not visualised'. Discussion with the consultant occurred and 'multiple abscesses drained. Washout with saline and pelvic drain placed.'

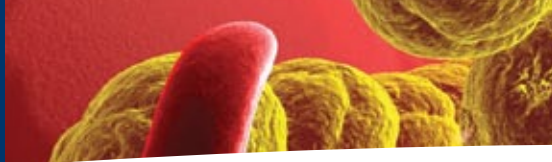
There was a brief period of hypotension in recovery which responded to fluid replacement. Urine volume was recorded as 650mLs at midnight. The IDC was removed early on day two but no volume recorded in chart. Blood results at midday showed: creatinine 0.25mmol/L, potassium 5.3mmol/L and normal gentamycin levels.

The gentamycin was stopped by the junior surgical trainee and their notes stated 'No IVT today. IDC out. Patient states - no urinary output.' The IDC was re-inserted late on day three but no urine was drained and the diagnosis of acute renal failure was made. It was unclear as to the cause at that time but gentamycin overdose and/or sepsis were considered most likely.

A period of careful clinical review by various disciplines (all well documented) and all supporting the diagnosis of acute renal failure probably caused by sepsis. The patient was given a bolus fluid replacement with IV frusemide but with no effect.

Early on day three the patient suffered a cardiac arrest. Intubation was difficult so a mask was used until the anaesthetist arrived and using a bougie, successfully intubated the patient. The patient required defibrillation with approximately half an hour to stabilise. The patient was transferred to CCU. A decision to undertake





laparotomy in view of probable sepsis with perforation was agreed by all disciplines as death was inevitable without. Dialysis was commenced but thought to be unlikely to change such severe metabolic acidosis.

Laparotomy was undertaken almost eleven hours after the cardiac arrest.

Notes recorded *'small bowel contents +++ washed out, marked peritonitis, hole in distal ileum, resected, small bowel ends stapled transversely, appendix caught up in inflammation removed, but looked normal. No convincing cause of problem found apart from perforated small bowel.'*

The post-operative plan was recorded thus: 'unless problem physiology, plan relook 48hrs. If appropriate re-join small bowel (if inotropes stopped).'

On day four, dialysis was recommenced but inotrope support, coagulopathy, substantial nasogastric tube drainage, aspiration pneumonitis, myoclonic jerks and anuria led to a family conference where it was agreed that no CPR was to be undertaken and inotrope support was to be limited if significant deterioration occurred. Several hours later, dialysis was stopped with no escalation of inotropes.

Over the next two days, the patient remained irritable with high inotrope need. No gag and no corneal reflex were noted. CT head scan confirmed no grey /white differentiation. After a family discussion, treatment was withdrawn and the patient died.

## Comment:

This morbidly obese patient had a pre-admission history of a progressive illness spanning at least two weeks.

After admission to hospital, in these scenarios, there is sufficient time to:

- establish the precise nature and stage of the disease process; its severity and systemic effects (almost certainly acute appendicitis associated with paracaecal phlegmon).
- make a carefully considered decision regarding management to include resuscitation with fluids and system antibiotics.
- plan a semi-elective or elective operative procedure if indicated, acknowledging the potential difficulty, and associated hazards and morbidity on operating on an 'angry and ugly' peri-appendiceal phlegmon.

**The attendance and participation of an experienced surgeon who is able to make the 'appropriate surgical' decision in this setting is mandatory.**







### 3. When standard care is refused.

---

This elderly patient was transferred to hospital due to significant pain post-ESWL for a single kidney stone. (Pre-ESWL, the patient's usual aspirin regimen had been ceased. However, no notes were available to show how long before the ESWL this had occurred).

On admission to hospital, the patient was haemodynamically stable (pulse rate 64, BP 125/60mmHg). Haemoglobin was 93g/L. The kidney stone fragment in the left renal pelvis was noted to be 6mmX4mm. It had been measured at 11mm in diameter on original imaging.

Ultrasound was arranged for the morning following admission. However, it took place in the afternoon following admission. The ultrasound showed a swollen, heterogeneous appearance of the left kidney with trace of free fluid. It was decided to proceed to CT scan to further delineate the degree of obstruction, the nature and size of the stone, and the pathology.

The preliminary diagnosis was perinephric haematoma and a conservative management plan was started.

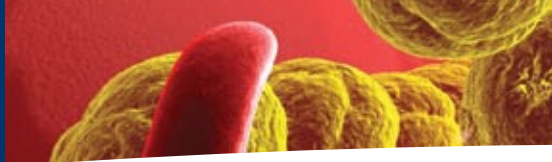
A CT scan confirmed diagnosis (the CT was delayed – it took place two days after admission). While in the CT suite, the patient became unstable and progressed to hypovolemic shock that was refractory to fluid resuscitation.

Due to religious beliefs, the patient declined any form of transfusion and, in discussion prior to and during de-compensation, declined any blood products. The patient was fully aware of possible outcomes resulting from refusing transfusion and blood products. The patient was reviewed by the critical care team but deemed to be unsalvageable without transfusing blood products and was 'near terminal' at that time. Cardiac arrest occurred shortly after and the patient was not resuscitated (as requested).

#### **Comment:**

**Early recognition of bleeding in any form should be considered and treated if possible. Take great care in treating the patient who declines transfusion, even when the pathology may not seem to be complex. Sometimes, however, the patient's wishes will not allow standard care in surgical practice.**





## 4. High speed: high mortality!

---

This young patient was found, unconscious with multiple injuries, following an unwitnessed single-vehicle accident. The ambulance worked at the scene for one hour and delivered the patient to the ED of a regional hospital at 1830hrs.

The patient was shocked and injuries included: left arm gleno-humeral dis-articulation/amputation, grossly contaminated and comminuted compound fractures of the left tibia and fibula, and deep wounds to the right shoulder, right thigh and abdominal wall.

Resuscitation was continued with IV fluids and blood replacement. Bilateral chest drains were inserted. The response to the resuscitation was poor.

A FAST assessment of the abdomen (for blood) was performed. It was found to be negative.

Transfer from the ED to the operating theatre occurred within an hour of admission.

Surgery included, subclavian artery and vein ligation, left above knee amputation, abdominal wound debridement, laparoscopy and subsequent laparotomy for splenectomy. A specialist general surgeon was involved.

A massive transfusion took place. Transfused blood and blood products included 25 units of packed cells, FFP and cryoprecipitate.

On transfer to ICU, the patient's blood pressure was very low despite inotropes. Cardiac arrest occurred and CPR was commenced – this ceased after 15 minutes and the patient was declared dead.

### **Comment:**

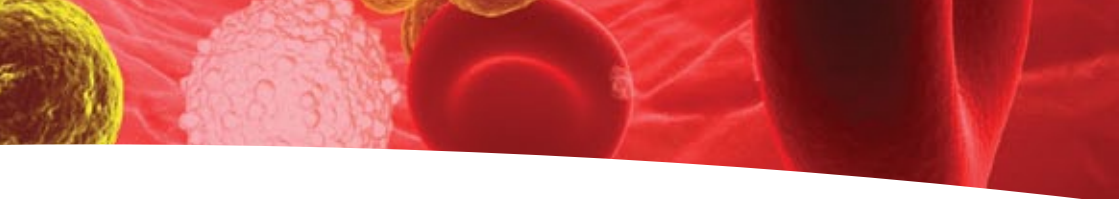
Despite excellent surgical care in this particular case, this patient was in dire circumstances on arrival at the hospital and unlikely to survive.

A strategy for surgery in a patient with such overwhelming injuries is always difficult. Several specialists may be necessary to provide the level of care the patient requires. In those circumstances, communication between the surgical and anaesthetic teams is absolutely essential.

Laparoscopy in a multi-trauma patient who has failed to respond to resuscitation is not indicated. Suspicion of intra-abdominal pathology should lead to laparotomy.

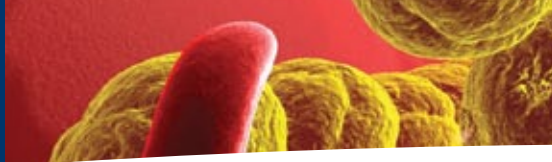
Where massive transfusion is required, protocols are helpful, both to record infused volume and proportionally replace factors, cells and volume. Poster-type documentation on the wall of the resuscitation area and operating room are practical in assisting with the sequence of transfusion products.

**A 'damage control approach' should be the initial management option. A gleno-humeral dislocation or a scapular-distraction injury suggests, at best, avulsion of axillary artery and, at worst, avulsion of sub-clavian artery from the innominate artery on the right or the aortic arch on the left.**



**These injuries are rarely compatible with survival and certainly account for refractory responses to massive transfusion. In this setting, it is clearly a waste of time, effort and resources to continue massive transfusion without defining the pathology, if necessary, by a thoracotomy or sternotomy or a combination of both.**





## 5. Remote-location decision making – phone a friend.

A middle-aged intoxicated patient was admitted to a remote hospital with a lacerated head injury after a fall. The patient was initially taken to a local primary care facility before being transferred to the remote hospital.

At the local facility, the head laceration was sutured by the on-duty nurse. The notes stated that the patient was ‘unconscious and unrousable’ with ‘unequal pupils’. The patient was subsequently intubated and ventilated. Retrieval was arranged.

An ICU entry states the patient arrived at the remote hospital at 0330 with handover to retrieval medical officer at 0730. Due to haemodynamic instability, the decision to extubate and palliate the patient was made at 1300. However, some brain stem function remained with the patient ‘biting suction tube and gagging on vomitus, moving legs when suctioned and pulling arm away after being held’. Due to this, the patient was re-intubated.

It is not clear how much input a neurosurgical team had in the decision making process until this point. There is documentation of the registrar being contacted and requesting a head CT scan.

The patient was transferred to a regional hospital for the head CT scan. This scan clearly demonstrated a non-survivable injury

and it was discussed with a neurosurgical registrar (at a major hospital) who stated that the patient was for palliation. Care was appropriate thereafter, culminating in brain-death shortly after admission to the regional hospital.

### Comment:

The time taken between hospitals needs consideration but, in these circumstances, the outcome may not have changed.

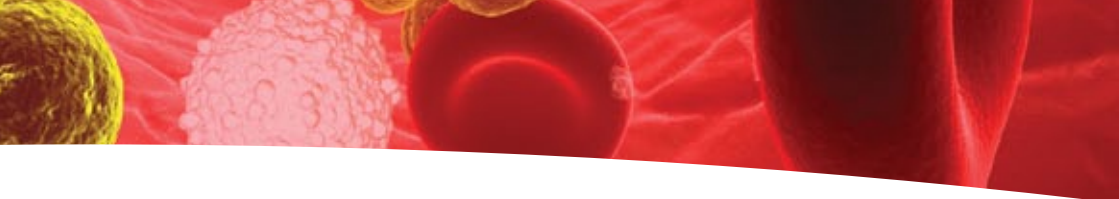
An intoxicated patient with a laceration needing sutures warrants extremely close supervision. With the benefit of hindsight, the patient should have been taken directly to a hospital where it was possible to intubate. To delay transfers to enable wounds to be sutured is contra-indicated.

A patient with a head injury, who ‘talks and dies’, has an extra-dural haematoma until proven otherwise. If the initial doctor had not thought of this possibility, then certainly the neurosurgical registrar should have.

Emergency ‘burr holes’ could have been considered. Many remote doctors do not have the where-with-all to undertake such a procedure, but this is probably the **only** intervention that could have saved this patient.

Some concern about the retrieval doctor’s decision to extubate the patient in the remote hospital; only to be re-intubated 3 hours later need consideration.

Such a decision needs to be made, with the guidance of a neurosurgeon, senior retrieval doctor, and/or intensivist, to extubate and



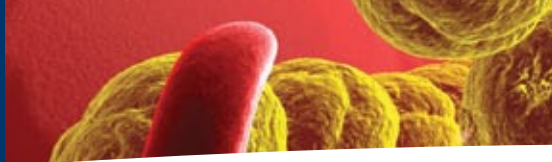
palliate, or the decision needs to be made to transfer the patient to a hospital where this can occur in a controlled manner.

The evocative nature of this case has only been brought further into focus by apparent indecision about the clinical state of the patient. The initial decision to extubate may well have been appropriate – the clinical state of this patient’s condition was dire and death inevitable. To re-intubate the patient and for transfer to be arranged thereafter must be questioned. The decision making processes at this point are not well documented. This is the area of significant concern.

**We again have to acknowledge the tyranny of distance in adverse outcomes of severe acute illness or injury.**

**At the point of primary care, fundamental skills of accurate clinical appraisal are mandatory so that timely advice can be sought from the appropriate ‘expert’.  
Pass the responsibility on to a ‘higher authority’!**





## 6. A simple case of sore elbow?

An elderly patient was admitted with a diagnosis of olecranon bursitis (which was discharging pus). Clinical examination confirmed that this patient was afebrile, hypotensive and dehydrated. The patient was admitted for investigation of elbow sepsis, and for fluid replacement and IV antibiotics.

On admission, a swollen left great toe was noted, and during admission, a swollen right metatarso-phalangeal joint was noted.

(This patient had been on warfarin for nearly a decade and had a history of alcohol abuse, liver disease, cardiac failure and renal failure.)

The patient was investigated but deteriorated slowly with decreasing renal function, and died two weeks post-admission.

The right MTP joint was thought to be caused by osteomyelitis. No investigations were done to confirm that diagnosis.

The site of the sepsis was never truly established. No blood cultures appear to have ever been taken. A week before admission, an aspirate of the bursa by the GP grew *Staphylococcus aureus* but a decision was made not to explore this surgically. It is possible that this decision may have made a significant difference to recovery.

The surgeon also chose not to explore the MTP joint. In retrospect, this decision was also unwise. The joint may have been another cause of sepsis (perhaps with different organisms).

The initial decision to treat this patient with IV gentamycin (single dose), when the patient was known to have already had renal failure, was concerning.

Clearly, the patient's health was deteriorating. Appropriate discussions with medical and ortho-geriatric services took place. The patient's family was kept informed at all stages. The patient and the family agreed 'not to resuscitate'.

### Comment:

In the elderly, especially in the presence of renal failure, it is possible to be septic without having a significant temperature. Hypothermia is indeed possible. The patient was profoundly hypotensive, was afebrile, but had a raised WCC over  $26 \times 10^9/L$ .

The gravity of this patient's predicament was not realised. A conscious decision not to intervene aggressively was taken by all parties.

**The treating team may have been lulled into thinking that the sepsis was under control because the patient was afebrile.**

Even if surgical debridement of the infected bursa had been performed and the MTP joint drained (if it was indeed the site of infection) this may not have necessarily altered the final outcome in this case.





## 7. Death after endoscopy – ‘surgical audit’ or not?

---

This patient had a history of alcohol abuse and, following a haematemesis, presented to a small rural hospital. Medical records document high alcohol intake prior to admission. A history of significant levels of smoking was also noted.

Plans for elective endoscopy after suspected melaena (two weeks prior) had been initiated but not confirmed. Stigmata of liver disease were noted and confirmed in the medical records.

Recorded on admission – *a pulse rate of 92, a systolic blood pressure of 110, and a haemoglobin level of 120gm/L. Following further bleeding, the blood pressure dropped to a systolic of 60.* It is impossible to tell from the medical records reviewed when a proton-pump inhibitor was first given.

Twenty hours after admission to the small rural hospital, the patient was transferred to a regional hospital.

On arrival at the regional hospital, the patient had a further haematemesis. The endoscopy team were contacted and arranged an urgent gastroscopy.

Before gastroscopy could be performed, the patient became unstable and failed to respond to resuscitation. Decision to withdraw treatment was made shortly after and the patient died.

### Comment:

Neither management plan nor request for regular observation was evident in the medical records, and while it is apparent that a Nexium bolus was given at some time during the morning, timing is not documented and rapid infusion was not commenced until 20 hours after presentation.

Patients with bleeding oesophageal varices are ‘high risk’ patients. In rural Queensland where transport delays are common, this patient’s transport should have been initiated 10-12 hours earlier. This would have allowed endoscopy to be performed in accordance with best practice.

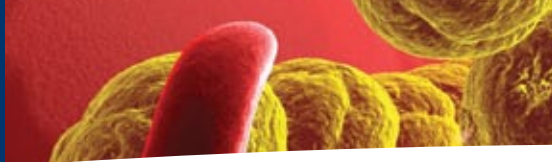
Early insertion of a wide-bore cannula may have assisted resuscitation and outcome.

Early endoscopy and banding after the sentinel event was indicated. (Prophylactic banding in specialised units may be appropriate.)

**Hospitals should adopt and implement a ‘medical early warning’ system in accordance acceptable practices. Clinical handover in line with recommendations is essential.**







## 8. Complex cases call for closer collaboration.

This patient was intoxicated before falling (unwitnessed) several metres onto bitumen. After the fall, the patient was discovered unconscious then carried some distance and put to bed.

The next morning, the patient was taken to hospital by ambulance because they were not able to move their arms or legs, and because they had urinary and faecal incontinence.

In the ED, the patient was awake and alert, but had no limb movement or sensation below cervical spinal nerve 6 (C6).

Xrays and a CT scan of the cervical spine showed an unstable fracture/dislocation at C6/7. A CT head scan showed an area of lowered density within the cerebellum, consistent with infarction. Regarding this, a neurosurgical opinion was obtained. No specific advice or treatment was suggested, other than the comment that the cerebellar infarction may have been the cause of the fall.

The unstable spinal fracture was treated with corpectomy and fusion was performed. The operation was uneventful and the patient was taken to the ICU intubated and ventilated.

Evidence of cardiovascular instability occurred throughout the following day with episodes of bradycardia. Later the following day, both pupils became fixed and dilated.

Emergency CT head scan and CT angiogram, confirmed the previous cerebellar infarction with more mass effect, and obstructive hydrocephalus. The CT angiogram showed evidence of a vertebral artery dissection. Neurosurgical input was sought once more and the patient was returned to theatre where a ventricular drain was placed and a posterior fossa decompression performed.

The patient recovered some papillary function but progress was poor and a subsequent CT scan some days later showed extensive posterior fossa and brainstem infarction.

The situation was thought to be irretrievable. The patient was extubated and soon died.

### **Comment:**

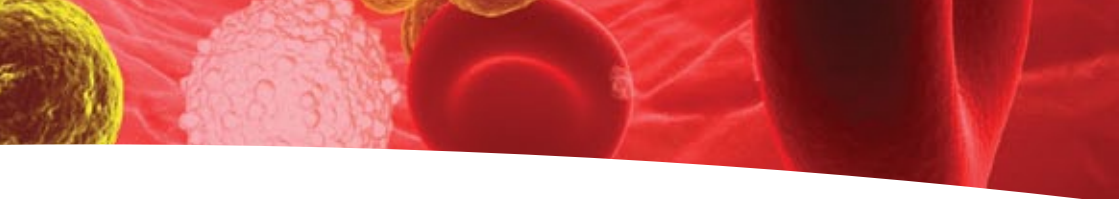
This death may have been avoided.

The first aid (or lack of it) administered by this patient's peers was clearly inadequate and may have contributed to the overall outcome.

Failure to call for an ambulance and the decision to lift and carry the patient after the fall may well have worsened injuries.

At hospital, a CT head scan identified a probable cerebellar infarction. At that point, management should have changed. If the cerebellar infarction was identified, the cervical surgery probably need not have proceeded without further investigation.

At presentation, a CT angiogram of the neck would have been appropriate. If the

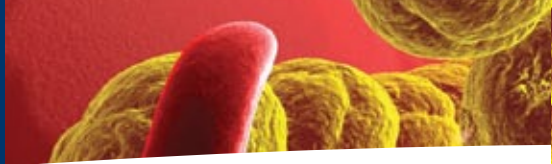


cerebellar infarction and vertebral artery dissection had been identified, the decision to proceed with the cervical fusion surgery may have been postponed. The risk with the cerebellar infarction was that cerebellar swelling and posterior fossa mass effect may have caused brainstem compression and hydrocephalus.

Knowing that a surgical procedure (for the fracture dislocation) would occur and that surgery may last for some hours, during which time clinical assessment could not be undertaken, it may have been prudent therefore that a ventricular drain be inserted prior to surgery. Intracranial pressure could then be monitored. In this case, because the neurological condition and the intracranial pressure were not monitored for many hours, when it became obvious that the cerebellar infarction was causing significant problems, it was really too late, and despite subsequent neurosurgical intervention, the damage was already done.

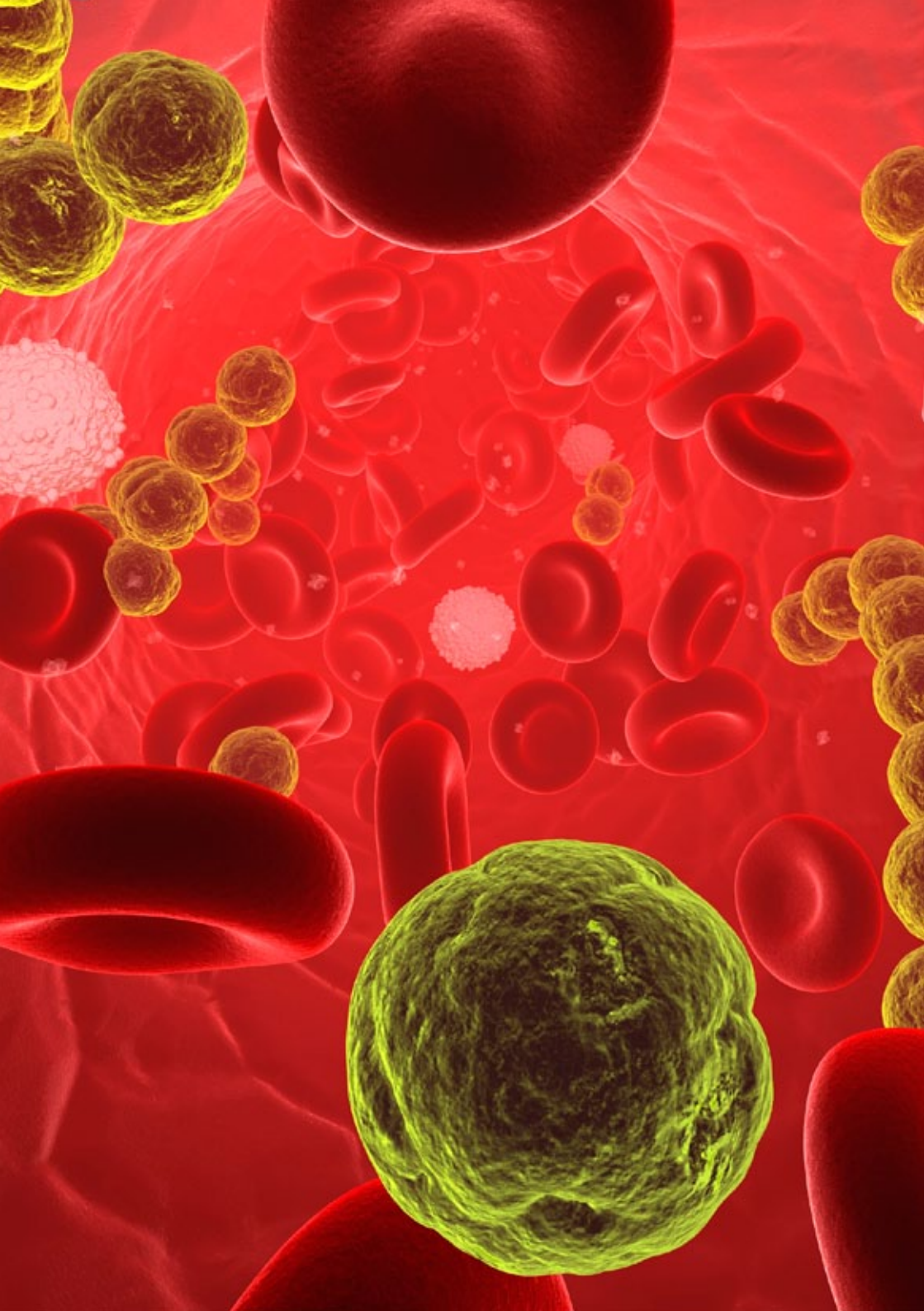
**Collaboration is an essential part of the management of the multiply injured patient. Complex cases call for closer collaboration.**





## Notes

A series of horizontal dotted lines for taking notes, starting below the 'Notes' header and extending across the width of the page.





ROYAL AUSTRALASIAN  
COLLEGE OF SURGEONS



**Queensland Government**  
Queensland Health



**Northern  
Territory  
Government**



Queensland Audit of Surgical Mortality



Northern Territory Audit  
of Surgical Mortality

Telephone: 07 3835 8671

Facsimile: 07 3236 9320

Email: [qasm@surgeons.org](mailto:qasm@surgeons.org)

Post: PO Box 79  
Spring Hill QLD 4004

Web: [www.surgeons.org/qasm](http://www.surgeons.org/qasm)

Telephone: 07 3835 8673

Facsimile: 07 3236 9320

Email: [ntasm@surgeons.org](mailto:ntasm@surgeons.org)

Post: PO Box 47  
Spring Hill QLD 4004

Web: [www.surgeons.org/ntasm](http://www.surgeons.org/ntasm)