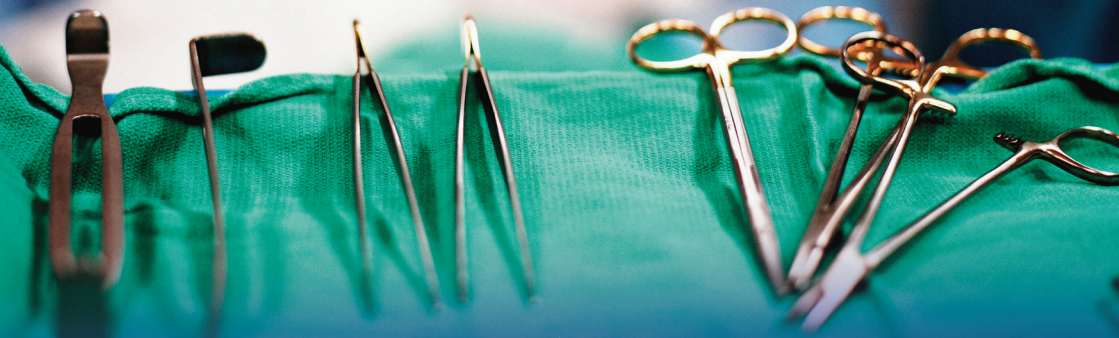



Victorian Audit of Surgical Mortality

Case Note Review Booklet

Third Edition - November 2011



Royal Australasian College of Surgeons



| | | |
|--|--|-----------|
| Contents | INTRODUCTION | 3 |
| | SUMMARY OF REVIEWERS COMMENTS ON INDIVIDUAL CASES | 4 |
| | EMERGING ISSUES | 8 |
| | CARDIOTHORACIC SURGERY | 9 |
| | Case 1: Deep sternal infection | 9 |
| | Case 2: Postoperative monitoring after cardiac surgery | 10 |
| | GENERAL SURGERY | 13 |
| | Case 3: Constipation is a symptom not a diagnosis | 13 |
| | Case 4: The clinical history is of great importance | 15 |
| | Case 5: Delay in definitive treatment for strangulated hernia | 17 |
| | Case 6: Management of Boerhaave Syndrome | 19 |
| | Case 7: Delay in definitive treatment for acting on clinical deterioration | 21 |
| | Case 8: Laparoscopic versus open hernia repair following surgery | 23 |
| | NEUROSURGERY | 25 |
| Case 9: Acting on clinical deterioration: head injury in the elderly | 25 | |
| Case 10: Headache plus cerebral aneurysm require urgent treatment | 27 | |
| ORTHOPAEDIC SURGERY | 29 | |
| Case 11: Poor communication | 29 | |
| UROLOGY SURGERY | 31 | |
| Case 12: No apparent plan of management | 31 | |
| Case 13: Clot retention can lead to death | 34 | |
| VASCULAR SURGERY | 36 | |
| Case 14: Gangrenous bowel after ruptured aortic aneurysm repair | 36 | |
| LIST OF SHORTENED FORMS | 38 | |



Introduction

The Victorian Audit of Surgical Mortality (VASM) audits deaths that occur whilst under the care of a surgeon in the public and private hospital sectors. As this peer review process is intended as an educational exercise, we have selected a number of cases that bring out specific clinical issues. The cases do not necessarily relate to the period since the last booklet, and may or may not have occurred in Victoria. They do, however, serve as topical and timely lessons for all surgeons and clinical team members.

All cases selected have gone through a second-line assessment (case note review) by a Fellow of the Royal Australasian College of Surgeons. The cases document critical incidents that are often system issues rather than the responsibility of the treating surgeon alone. The assessments have been edited to ensure that the patient, hospital involved, treating surgeon and assessor remain anonymous.

Qualified Privilege prevents us from sending assessment feedback to anybody other than the treating surgeon. This means hospital management only receive indirect feedback on cases of patients who died in their hospital. The surgeon can of course share the outcome of their assessment with relevant staff. Where there are obvious system issues it is important that hospitals are aware and react to address these issues as appropriate. It is also important that VASM attempt to address emerging adverse trends. The failure to recognise and react to 'clinical deterioration' is such an issue. VSCC in conjunction with VASM are currently planning a seminar on Clinical Deterioration. This will be held in early 2012 and will target hospital medical and nursing staff.

We feel there are important lessons in this publication and it should be made available to all those responsible for delivering the care that resulted in the outcomes presented. We recommend the cases presented might be used as teaching aids. We can provide additional copies as necessary.

The VASM staff take this opportunity to thank all surgeons and hospitals participating in VASM. We hope you find this publication of value.



Summary of reviewers comments on individual cases

Case 1

Deep sternal infection requires aggressive treatment

The operation itself was satisfactory, but the decision not to reoperate for sternal wound infection is difficult to understand. Reoperation was indicated, and if it had been performed sooner the sepsis would have been controlled. The resulting multisystem organ failure in this immune compromised patient was perceived to be secondary to this uncontrolled sepsis.

Case 2

Postoperative monitoring after cardiac surgery

Significant clinical deterioration after cardiac surgery was managed ineffectively without prompt review or change in treatment. Renal and significant left ventricular failure (LVF) developed rapidly, followed by atrial fibrillation (AF) and a rapid ventricular response plus worsening respiratory condition. AF in patients with significant left ventricular hypertrophy (LVH) often results in significant deterioration in their cardiac output as appears to have been the case here.

Case 3

Constipation is a symptom not a diagnosis

There have been a number of tragedies over the years where patients have presented to the medical profession with significant symptoms of abdominal pathology and been discharged with a diagnosis of 'constipation'. In this case, the patient's constipation was secondary to complications of diverticular disease that resulted in septic shock and death.

Establish a probable diagnosis and confirm with investigations where possible

With obvious intra-abdominal pathology and sepsis, surgery may be inevitable. Nowadays we have rapid access to computed tomography (CT) and other advanced investigative modalities to guide our approach. Perhaps in this case a short delay for CT might have changed the outcome.



Remain open minded

The operative findings did not exclude other diagnoses and yet the diagnosis of appendicitis appears to have been rigidly adhered to for longer than appropriate. The true source of the sepsis was not discovered until the third laparotomy.

Case 4

The clinical history is of great importance

When clinical history and findings do not match results of investigation, be cautious. When the initial diagnosis becomes less valid, consider other diagnoses before acting on the initial presumed diagnosis.

Case 5

Delay in definitive treatment for strangulated hernia

When bowel obstruction is diagnosed in association with a tender, irreducible hernia, the potential for ischaemic bowel must be considered high and is a strong indication for early definitive surgery. Such cases must not be allowed to languish on conservative treatment without proper discussion with the on-call surgeon.

Case 6

Management of Boerhaave Syndrome

The diagnosis can easily be missed. Even with early recognition and prompt treatment a ruptured oesophagus is not easy to manage.

Case 7

Acting on clinical deterioration

A decision for conservative management of an elderly patient with suspected bowel perforation during colonoscopy was made. This was with the proviso that close monitoring for clinical deterioration would be undertaken. Clinical deterioration was recorded overnight but was not acted on or communicated to the consultant until too late. There must be a system for monitoring clinical deterioration and 'handing up' when certain defined parameters have been reached.



Case 8

Laparoscopic versus open hernia repair following surgery

Bowel injuries can occur and they can occur 'off screen'. The operating surgeon can be blissfully unaware. The sooner the diagnosis is made the better, as then there is every chance that a primary repair will be very satisfactory. Surgeons should also note that in the event of a delayed diagnosis of a bowel perforation, a live patient with a stoma is infinitely preferable to a dead patient.

Case 9

Acting on clinical deterioration

There are particular issues in managing elderly patients. Cerebral atrophy can offer a false sense of security when addressing cerebral haemorrhage, as there is often a delay in overt clinical deterioration. As such, regular clinical and neurological assessment is paramount. This appears to have been lacking.

Case 10

Headache plus cerebral aneurysm require urgent treatment

A young person with severe headaches, visual disturbance and magnetic resonance imaging (MRI) evidence of a large aneurysm containing mural thrombus, was not referred to an outpatient clinic until several days later.

Case 11

Poor communication

Interdisciplinary communication is an important facet of achieving a high standard of care. Supervision of trainees is important, especially in complex cases in patients with comorbidities.



Case 12

No apparent plan of management

This case also highlights some of the difficulties faced by second-line assessors. The case record was devoid of useful information on which to base an assessment. There was no documented clear management plan. The impression given by the case record is that the junior medical staff managed the case without consultant input. If this is correct it is extremely unfair to junior staff and not surprising that timely intervention did not occur.

Case 13

Clot retention can lead to death

Following prostatectomy, inadequately managed postoperative clot retention resulting in ongoing pain and blood loss can lead to fatal sequelae. If repeated manual washouts of clots on the ward fail, then a return to theatre is indicated.

As a general statement, hospital medical staff should be proactive if ward procedures by nursing staff are unsuccessful. This means a registrar needs to take over at the bedside. This applies to insertion of intravenous (IV) lines, nasogastric tubes and removal of difficult drain tubes.

Case 14

Gangrenous bowel after ruptured aortic aneurysm repair

Classical surgical emergencies remain a challenge, requiring prompt recognition in the Emergency Department (ED) and immediate involvement of the surgical team.



Leadership in patient care

- In complex cases, there must be clear demonstrable leadership in patient management. The treatment plan for each patient should be understood by all involved with the patient's care.

Documentation of clinical events and plans

- The case record is an essential tool for identifying clinical trends and management plans. As such the case record must contain clear and accurate documentation of events and plans.

Failure to act on evidence of clinical deterioration

- This is an issue that is recognised throughout Australia and internationally.
- When clinical deterioration occurs in a patient and there is no clear cause, remember the cause may be related to something outside your specialty knowledge base.
- Clinical findings must be considered along with the results from any investigations.
- Clinical deterioration must not just be recorded, it must be acted upon.

The potential outcomes from the probable clinical diagnosis must be considered when developing a treatment plan.



Case 1: Deep sternal infection

Summary

A middle-aged patient, known to be on immunosuppressive therapy for rheumatoid arthritis, underwent a double valve replacement. The operation went well.

Approximately two weeks postoperatively, 'ooze' developed from the sternal wound. Days later the incision reopened. From the notes, the patient had a deep sternal wound infection without endocarditis and sepsis. The patient was not taken back to the operating room for formal sternal debridement. A vacuum dressing was applied at some stage, but from what can be ascertained this was not as part of a surgical procedure. The patient's sternum was reopened just before death. The patient died some weeks postoperatively in the intensive care unit (ICU).

Reviewer's comments

The operation itself was satisfactory, but the decision not to reoperate for sternal wound infection is difficult to understand. Reoperation was indicated, and the sooner it was performed, the more likely that sepsis would have been controlled. The resulting multisystem organ failure in this immune-compromised patient was secondary to this uncontrolled sepsis.



Case 2: Postoperative monitoring after cardiac surgery

Summary

An elderly patient with severe aortic stenosis and multiple comorbidities including chronic obstructive pulmonary disease (COPD), pulmonary hypertension, persistent AF, and mild renal impairment underwent an aortic valve replacement (AVR). Preoperative transthoracic echocardiogram (ECHO) identified severe aortic stenosis with moderate concentric LVH and a small left ventricular cavity size, with hyperdynamic systolic function.

Increased late systolic flow velocity in the distal left ventricular outflow tract (LVOT)/mid left ventricle (LV) cavity region was also identified. Both the IV septum and posterior wall were thickened. Preoperatively the findings of severe aortic stenosis were addressed. but no comment was made of other ECHO findings.

At surgery, AVR with 21 mm bioprosthesis, pulmonary vein isolation and excision of left atrial appendage were performed. The pre-bypass intraoperative transoesophageal echocardiogram (TOE) confirmed aortic stenosis, and identified a hypertrophic LV with normal systolic function and a prominent septal bulge, but no systolic anterior motion. The intraoperative findings of the LVOT were not described. Post-bypass TOE did not address the LVOT. The intraoperative course was uneventful and the patient was transferred to ICU around midday. The initial postoperative course was uneventful with extubation within several hours. The patient was dyspnoeic overnight and a right pneumothorax, requiring insertion of an intercostal catheter (ICC), was identified following day. The cardiac index, filling pressures and vascular resistance were within normal limits. Urine output was satisfactory. The patient was transferred to the ward postoperatively.

The patient remained oliguric despite IV fluids. This was associated with worsening oxygen saturations and increased oxygen needs. Following review by the overnight surgical cover, no further action appears to have been taken. Deteriorating respiratory function and persistent oliguria were noted by the surgical team the following day. Stat doses of Lasix (at the same dose) were given with no improvement in urine output. Regular nebulisers of Salbutamol were administered.

The patient next developed AF with a rapid ventricular response. Systolic blood pressure (BP) fell below 100 mmHg and respiratory rate was > 24 breaths per minute. Continuous positive airway pressure and supplemental oxygen titrated up to 100%



were given. A couple of days following admission to the ward, there was a medical emergency team (MET) call for low oxygen saturations. A repeat dose of Lasix (dose unchanged) was given again with no improvement in urine output. Persistent oliguria and LVF failed to respond to the treatment given.

The patient was returned to ICU with further Lasix again failing to have any effect. Respiratory function deteriorated, necessitating intubation. Systolic BP became labile and required several boluses of Aramine followed by increasing infusions of vasopressors. Haemofiltration was commenced. Systemic BP remained low despite increasing vasopressors, inotropes, Aramine and IV fluids. The patient died shortly thereafter.

Reviewer's comments

On reviewing this case the following points can be made.

This patient deteriorated significantly after surgery. By the morning of day one postoperatively, the patient had established renal and significant LVF. The treatment that was instituted by the surgical team was ineffective, but did not prompt a review or change in treatment. There was further deterioration with AF and a rapid ventricular response plus worsening respiratory condition. AF in patients with significant LVH often results in significant deterioration in their cardiac output, as appears to have been the case here.

Soon after developing AF, a MET call for low saturations prompted an ICU review. Again the treatment of the LVF and oliguria was ineffectual and the patient was taken to ICU, intubated and commenced on haemofiltration. The failure of timely intervention to accelerate treatment modalities after an extended period of deterioration could have contributed to the death. The timeliness of intervention by both the surgical and ICU teams are areas of concern.

The failure to respond to treatment should have prompted further investigation and closer monitoring in ICU. Despite having a swan sheath in situ, no invasive haemodynamic monitoring of cardiac indices was undertaken, or at least recorded, yet high dose vasopressors and inotropes were used. An ECHO was required to assess LV function, filling status, aortic valve function and possible LVOT obstruction.

Preoperative ECHO identified a hypertrophied ventricle with flow acceleration across the LVOT/ mid LV cavity. Intraoperatively a prominent IV septum was also noted, but its



possible contribution to LVOT obstruction was not described. In the setting of severe LVF postoperatively, the possibility of LVOT obstruction should have been considered. High dose inotropes and a rapid ventricular rate would have worsened this condition. The contribution of the inotropes and vasopressors to the rapid deterioration of the patient is an area of concern that may have contributed to the death. In addition, the failure to address the issue of flow acceleration across the LVOT intraoperatively may have contributed to the death and should have been considered in the preoperative planning and intraoperative decision making.



Case 3: Constipation is a symptom not a diagnosis

Summary

A middle-aged, non-insulin dependent diabetic patient presented to the ED. The patient was described as confused, in pain and having an acute abdomen. Examination concluded the patient was in septic shock with tachypnoea and tachycardia. Abdominal findings were of tenderness, maximal in the right iliac fossa. An elevated white cell count was noted.

Nearly a week earlier, the patient had presented to ED with pain and constipation. At that time, a diagnosis of 'constipation' was made. There were no notes or record of investigations relating to this presentation. The postoperative medical record described numerous visits to the patient's local medical officer (LMO) with similar symptoms prior to and following this initial presentation.

After reviewing the patient in the ED, the surgical registrar recommended urgent laparotomy. A midline laparotomy was performed and an abscess was found in the right pelvis with adhesions and necrotic debris. No appendix was identified but a diagnosis of necrotic appendix with associated abscess and peritonitis was made. Drain tubes were placed and the abdomen was closed. Postoperatively the patient was transferred to ICU, still ventilated.

The patient remained in a septic state and unresponsive to all but significant external stimulation. Due to instability from ongoing sepsis, the patient returned to the operating room a few days later for a repeat laparotomy. No new pathology was identified and the abdomen was washed out and the wound closed with drain tubes in place. Further clinical deterioration necessitated a third laparotomy. At this operation, perforated diverticular disease was identified as the cause of the sepsis and a Hartmann's procedure performed.

There was progressive deterioration with the development of multi-organ failure. A subsequent CT scan demonstrated multiple liver abscesses and ongoing problems in the pelvis. At a fourth laparotomy, disruption of the rectal closure with faecal leakage was identified. The CT scan revealed multiple intracerebral abscesses. Progressive multi-organ failure led to death.



Reviewer's comments

This non-insulin dependent diabetic patient presented to the ED with a provisional diagnosis of septic shock secondary to peritonitis. Nearly a week before this presentation, a diagnosis of 'constipation' had been made in ED. There had been other visits to the patient's LMO related to the same problem. It would be interesting to review this history of presentation.

The surgical registrar recognised an acute abdomen and decided the need for an urgent laparotomy. There were no notes relating to this decision. A diagnosis and plan of management was, we presume, relayed to the surgeon who accepted the plan for surgery. The registrar's decision may have been incorrect but, having accepted the decision, the surgeon performed the operation, perhaps expecting to find complicated appendicitis. Had the registrar proceeded to stabilisation and some investigation of the patient, a different outcome might have been achieved. Peritonitis is not, in this situation, an indication for urgent surgery. However, having embarked on the operation the findings were accepted as secondary to appendicitis.

A correct diagnosis was made at neither the initial laparotomy, nor at the second laparotomy for ongoing sepsis. This ongoing sepsis was an indication that either the septic focus had not been dealt with, or the original diagnosis was incorrect, or a complication had resulted from the first operation. The second laparotomy failed to identify other pathology and an untreated septic focus remained in the abdomen. It was not until the third laparotomy that the true focus was identified. At this stage the patient may have been on an inevitable path.

This patient probably presented to ED initially with complications of diverticular disease. A diagnosis of 'constipation' was made. It is amazing that in these days a diagnosis of 'constipation' can even be entertained. We can all recall similar outcomes in patients sent home with a diagnosis of constipation.

'Constipation' is a symptom, never a diagnosis.

When this patient presented with septic shock as a consequence of complicated diverticular disease, there was probably still opportunity to retrieve the situation with surgery. Failing to diagnose the cause at initial surgery, and surgical interference with the inflammatory adhesions in the pelvis, may have negatively influenced the outcome. The same applies to the second operation and unfortunately when the correct diagnosis and surgical management were made at a third operation, the patient's condition was on a declining path.



Case 4: The clinical history is of great importance

Summary

A middle-aged patient with significant comorbidities including chronic renal failure and hypertension and with a history of renal transplantation, presented to ED with sudden onset of headache and mild right-sided abdominal pain, radiating through to the back. Prior to presentation the patient had vomited, became faecally incontinent and collapsed striking their head but with no loss of consciousness. On admission, hypotension and acidosis were noted and a diagnosis of septic shock was made.

Appropriate rapid and aggressive resuscitation was commenced in ED with insertion of femoral arterial and venous lines and parenteral broad spectrum antibiotic administration. Clinical input was gained from surgery, renal and ICUs. Ultrasound of the abdomen, chest x-ray and CT scan of the head were performed. Acute cholecystitis was diagnosed by the radiologist who reported a 'necrotic gall bladder'.

The patient was noted to be moderately obese, anuric and acidotic with pH levels below 7.35. A focused assessment with sonography for trauma ultrasound did not demonstrate any obvious free intra-abdominal fluid. The patient was intubated, ventilated, commenced on inotropes and admitted to ICU. The initial abdominal examination mentioned no mass or significant abdominal guarding, only mild right upper quadrant tenderness. A presumptive diagnosis of septic shock due to acute cholecystitis and/or cholangitis was made. 'Dark bile' was obtained from percutaneous cholecystostomy performed by a radiologist on the day of admission.

As there was no clinical improvement and the patient remained anuric; laparoscopic cholecystectomy was planned for the following day. At operation, an oedematous, but not gangrenous, gallbladder was described. The laparoscopic cholecystectomy appeared to be uneventful.

The patient did not improve despite ongoing support following surgery. The day after cholecystectomy, ECHO and CT scan demonstrated a dissecting abdominal aortic aneurysm (AAA) with pericardial effusion and some degree of tamponade. This was considered inoperable by the specialist vascular surgeon and, once diagnosed, the patient's treatment was palliative.



Reviewer's comments

There was a delay in making the correct diagnosis, which probably did not significantly contribute to the outcome, but did result in an unnecessary surgical procedure. Had this diagnosis been made earlier, appropriate palliative care could have been implemented from the outset.

Whilst sepsis with hypovolemic shock is an appropriate differential diagnosis in a patient presenting with peripheral collapse and peripheral circuitry failure, this presentation of headache, faecal incontinence with sudden collapse and minimal abdominal signs, make it important to consider other differential diagnoses including aortic catastrophes. It is not clear whether the original ultrasound commented on the abdominal aorta. It was not clear from the notes at which level the diagnosis was made, but once made, it appears not to have been questioned, despite the lack of support from clinical signs or response to percutaneous cholecystostomy. This case study is a good illustration that a provisional diagnosis must always remain just that until confirmed and must always be subject to revision and change. It would have seemed prudent to attempt to confirm the diagnosis of acute gangrenous cholecystitis by further imaging prior to subjecting this exceedingly high risk patient to surgery. Unless there is pericholecystic gas to suggest gas producing organisms, an ultrasound cannot reliably diagnose necrosis of the gallbladder. This diagnosis should have been viewed with circumspection. The liver function tests (LFTs) were completely normal, and a necrotic gall bladder or ascending cholangitis might be expected to be associated with some abnormality of LFTs.

Surgical decision making in the initial stages of management in this patient could possibly have been better. Quite apart from the fact that there were no records written by a senior surgical team member in the first 24 hours, there was certainly nothing written which evidenced consideration of other diagnoses apart from a necrotic gall bladder. CT scans of the abdomen or chest were not considered and there was no clinical assessment to indicate differential pulse characteristics in the upper and lower limbs or clinical signs of a dissecting aneurysm.

There are also some concerns about the choice of clinical management. If there was a necrotic gall bladder, then cholecystostomy was not appropriate and even likely to lead to complications. Drainage, followed by removal of a necrotic gall bladder by open or laparoscopic cholecystectomy, is the way to manage a patient with metabolic acidosis and septic shock secondary to that problem.



Case 5: Delay in definitive treatment for strangulated hernia

Summary

An elderly patient presented to ED with a 24-hour history of abdominal pain and vomiting. The night surgical registrar noted the pain was colicky and central, with no bowel action reported for several days. The patient was on Warfarin for AF and noted to have a history of chronic cardiac failure due to non-ischaemic cardiomyopathy. On examination, observations were stable and the patient was reported to be comfortable and not unwell in appearance. An irreducible right inguinal hernia was described and noted to be tender.

In ED, investigations demonstrated a high white blood cell count (WBC), an elevated international normalised ratio and abnormal LFTs. Abdominal x-ray showed multiple air/fluid levels in dilated loops of small bowel. The treatment plan was for admission, reversal of Warfarin, nasogastric suction, IV fluids and surgery the following day.

Surgery occurred nearly 24 hours after presentation and almost two days after onset of symptoms. The McEvedy approach was used, and two adjacent segments of infarcted small bowel were resected and a small bowel anastomosis was performed using a stapling technique. The femoral hernia was repaired by excision of sac and suture.

The patient remained hypotensive following surgery requiring inotropic drugs and transfer to ICU. Over the next week, there was ongoing deterioration in ICU with death nearly a week after the operation. The cause of death was deemed to be multi-organ failure caused by septic shock secondary to gangrenous small bowel in a strangulated femoral hernia.

Reviewer's comments

The main area of concern is the inappropriate delay between the patient's arrival in ED and surgery, nearly 24 hours later. Clearly, the night surgical registrar who assessed the patient should have discussed the patient with the consultant. If surgery was felt to be unnecessary overnight, then it should at least have been scheduled for early in the morning.

Was the operative approach (McEvedy) the best for this presentation? The operation notes did not mention whether the remainder of the small bowel was inspected. This



can be difficult through a McEvedy approach. When gangrenous small bowel was found, perhaps a formal laparotomy, at which the entire small and large bowel could have been properly examined, might have been appropriate. The presence of another segment of gangrenous bowel may not have been considered. A post-mortem should have been carried out.

Suggested changes in practice:

- Notify the on-call surgeon of any patient who is deemed to require admission.
- Consider a formal laparotomy when multiple segments of ischaemic bowel are found within a strangulated femoral hernia.



Case 6: Management of Boerhaave Syndrome

Summary

A middle-aged patient presented to ED in the evening with upper abdominal pain following an episode of vomiting which coincided with the onset of pain. Findings in ED were of a tachycardic patient in some distress with surgical emphysema on the right side of the neck. A CT scan with gastrografin was performed several hours after presentation, which confirmed likely perforation in the distal oesophagus with pneumomediastinum and free retroperitoneal gas. The surgical team were involved in ongoing management. A long history of heavy alcohol intake was recorded.

Shortly after the CT scan, upper gastro intestinal endoscopy was performed and a covered stent placed over the defect. The patient was then admitted to the high dependency unit. Oxygen saturation was recorded as 94% but inspired oxygen was not recorded. In the morning, shortly after perforation, the risks and benefits of thoracotomy were discussed with the patient. The patient, who appears to have been fully conscious, was described as adamantly opposed to surgery. Further clinical deterioration and discussions with the patient finally led to consent for surgery later that afternoon, nearly a day and a half after perforation.

Thoracotomy through the left fifth interspace identified gas and fibrinous exudate in the mediastinum, but no gross contamination. Mediastinal drains were left in situ. Laparotomy findings were of free (turbid) peritoneal fluid with gas in the lesser sac and omentum. In addition to drains, a feeding jejunostomy and defunctioning gastrostomy were created.

Postoperatively the patient was transferred to ICU. After extubation there were ongoing respiratory problems with poor gas exchange. Nearly a week after surgery the patient remained febrile and acute clinical deterioration required reintubation. Clinical improvement again occurred and the patient was discharged to the ward nearly a month after admission to ICU. During this time, CT-guided drainage of retroperitoneal recollection was performed on the patient. The patient subsequently died nearly a week later.



Reviewer's comments

It is hard to tell if this was a preventable outcome as mortality from Boerhaave Syndrome with delay in treatment for more than 12 hours is close to 30% and rises to 50% if the delay is over 24 hours.

- There was a delay in diagnosis as a result of the patient's late presentation to ED. The patient's initial unwillingness to undergo surgery also added to the delay in definitive treatment.
- As the best outcomes are associated with early diagnosis and definitive surgical management, the initial endoscopic stent may have been inappropriate.

Expert opinion - management of Boerhaave Syndrome

The best outcome will be achieved by early surgery and repair. A gastrograffin swallow or swallow combined with CT are still worthwhile. This will determine the level and the best side for surgical approach. For the surgeon who is used to video-assisted thoracoscopy (VATS) a thoroscopic approach is reasonable, but otherwise a formal thoracotomy should be performed. A thoraco-abdominal approach is a bad incision and very painful with an unstable costal margin. Any defect should be closed with fine interrupted sutures. A pleural flap is an optional extra. Where there is a delay in treatment, primary closure may not be appropriate or feasible. Under those circumstances, T-tube drainage into the defect plus ICCs are best. The contralateral side usually requires a drain, ideally inserted thoroscopically, but if there is minimal fluid on CT this side can be treated expectantly.

For patients with intra-abdominal free gas and/or fluid, laparotomy with lavage, draining gastrostomy and feeding jejunostomy are required. If a stent has been placed in the oesophagus then an absorbable suture should be placed full thickness through the wall of the oesophagus or stomach to anchor it into position (much like the old fashioned Celestin tubes). The problem with stenting is that there is no stricture and therefore nothing to hold the stent in position. Migration and all the ensuing problems are frequent. It may be that stenting was performed in this case because of the patient's refusal to accept surgery.



Case 7: Delay in definitive treatment for acting on clinical deterioration

Summary

An elderly patient with significant cardiac disease underwent gastroscopy and colonoscopy to investigate dysphagia, altered bowel habit and weight loss. A perforation was diagnosed during colonoscopy and the procedure was abandoned. Initial management was conservative with observation and antibiotics. The following day, because of worsening pain, tenderness and hypotension, the patient underwent laparotomy with washout and exteriorisation of a sigmoid perforation. Treatment was withdrawn at family's request and the patient died shortly after laparotomy from acute myocardial infarction (AMI) and severe acute pulmonary oedema (APO).

The hospital case notes documented the sequence of events well. The operation findings at laparotomy were deficient in the operation report with no information on the size of the perforation, the degree of contamination by faeces or the presence of purulent peritonitis.

Reviewer's comments

Although there must always be concern with performing colonoscopy in elderly patients with cardiac disease, in this case the indication seemed reasonable.

The need for laparotomy versus conservative treatment is often a difficult decision. A conservative approach was adopted, as the erect chest x-ray demonstrated no free gas under the diaphragm and as the surgeon appeared to doubt if there actually was a perforation. Perhaps a CT scan of the abdomen might have added to the clinical picture and helped formulate the treatment plan.

Junior staff faithfully recorded the overnight deterioration and abdominal signs suggesting the onset of peritonitis in the notes, but did not seem to act or inform the consultant of what was a clear indication for urgent laparotomy.

The acute mesenteric ischaemia (AMI) and resulting APO may not have been preventable, but did contribute considerably to the patient's death.

It is important to consider comorbidities in elderly patients when considering colonoscopy. If a colonoscopy is performed to look for a possible bowel cancer, but the



patient is not deemed fit for major resection, then colonoscopy may not be appropriate. Some may argue however, that if polypectomy can be performed this may prevent bowel cancer.

In patients who are being actively observed, with a provisional diagnosis of possible bowel perforation, then evidence of deterioration or progression of signs must be passed on to the senior consultant responsible. These worsening signs cannot be ignored and are often indications for laparotomy.



Case 8: Laparoscopic versus open hernia repair following surgery

Summary

An elderly patient with significant comorbidities had a recurrent or residual right groin hernia following an open mesh repair of an upper abdominal incisional hernia, resulting from an open AAA repair a few months prior. The groin hernia was reported to be highly symptomatic. A laparoscopic extraperitoneal mesh repair was attempted but the balloon used to dilate the extraperitoneal space tore the underlying peritoneum. The operating surgeon, aware of the risk of bowel injury, inspected the lower half of the peritoneal cavity and, finding nothing amiss, proceeded to perform a laparoscopic extraperitoneal repair and closure of the peritoneal tear with staples.

The following morning the patient was clearly unwell and was returned to the operating room for a laparotomy. A tear in a segment of small bowel adherent to the previous mesh hernia repair was repaired. The clinical course following this procedure was never truly satisfactory. The patient required ongoing parenteral nutrition, Candida was grown from blood cultures and there were significant ongoing clinical and nursing concerns. Enteric content began to leak through the wound triggering a further laparotomy with formation of an ileostomy. The patient had a very complicated slow recovery, requiring further laparotomies for sepsis. A fall resulted in a fractured neck of femur and ultimately the patient died.

Reviewer's comments

This patient had a long midline incision from the AAA repair and mesh in the upper abdomen. This made a laparoscopic approach much more difficult and problematic. Although laparoscopic extraperitoneal hernia repair is an excellent method of repairing recurrent groin hernias, it seems likely in this case that the main hernia may have been pre-vascular, perhaps relating to the previous aortic surgery. This hernia is very difficult to repair any way other than a pre-peritoneal repair.

Open mesh repair was an alternative, through a transverse supra inguinal incision or the midline. However, both these approaches would have carried increased respiratory and possibly cardiac risk. On balance, the decision to perform the operation laparoscopically was probably reasonable.



Once a peritoneal tear was identified, inspection of the peritoneal cavity was mandatory. A limited exploration appears to have been done and it is unfortunate that the bowel injury was in fact in the upper abdomen and not easy to visualise through the standard ports that would have been inserted for this operation. It might have been advisable to enlarge one of the lower abdominal ports into a 10 mm port to enable the camera to be turned upwards to inspect the upper abdomen. This might have identified the bowel injury, although it still could have been missed.

The next day, the complication was identified promptly and a correct decision to perform a laparotomy was made. At that operation, once the bowel injury was clearly identified, there was a choice between repairing the bowel or creating an ileostomy. This patient had multiple medical comorbidities and had now had enteric content in the abdomen for more than half a day. The patient was at risk of breakdown of any repair of the small bowel. Depending on the clinical status, oxygen requirements and need for inotropes, consideration should have been given to formation of an ileostomy rather than repairing the bowel injury. It is not clear if this was considered. It is worth noting that had a stoma been performed at this stage, the patient might have recovered uneventfully.

The small bowel repair did break down and a stoma was ultimately required. It is nearly always possible when looking back at notes to suggest that intra-abdominal sepsis could have been diagnosed a little bit earlier than it in fact was. It is clear that there was close surgical attention at all times.

The remainder of the hospital course is understandable for an elderly person with comorbidities. I have no criticisms of the management.

I believe this case should sound a warning to surgeons undertaking laparoscopic procedures and in particular laparoscopic hernia repair. Bowel injuries can occur and they can occur 'off screen'. The operating surgeon can be blissfully unaware. The sooner the diagnosis is made the better, as then there is every chance that a primary repair will be very satisfactory. Surgeons should also note that in the event of a delayed diagnosis of a bowel perforation, a live patient with a stoma is infinitely preferable to a dead patient.



Case 9: Acting on clinical deterioration: head injury in the elderly

Summary

An elderly person fell and struck their head. A brief loss of consciousness was recorded. The ambulance team arrived within minutes from request and recorded a Glasgow Coma Score (GCS) of 15 and a laceration and haematoma above an eyebrow. A 'facial droop' was also noted. Comorbidities were described as congestive cardiac failure, COPD, epilepsy and recent cataract surgery. Regular medications included salbutamol and aspirin.

The patient was triaged in the ED, followed by examination by a junior medical officer (JMO) and CT scan of the brain and cervical spine. The record of examination by the JMO was very brief and indicated no neurological abnormalities. CT scan demonstrated a right subdural haematoma with a small midline shift, haemorrhage and contusion of the left frontal lobe. Although the CT of cervical spine demonstrated no fractures, it raised the possibility of an epidural haematoma. The case notes recorded a discussion with the neurosurgical registrar after review of CT scans. The management plan was admission to a ward with four-hourly neurological observations. The last set of observations in ED recorded a GCS of 15 and mild weakness of the left leg.

On transfer to a ward, the GCS started to fall in addition to severe weakness of the right leg. There was no record of examination of the pupils or of any attempt to notify medical staff of this marked deterioration in neurological status. The next review by nursing staff occurred four hours later. At this time the patient was found to be comatose and in asystolic arrest with evidence of having vomited. A code blue was called and after prolonged resuscitation, cardiac output was regained and the patient transferred to ICU. By this stage the patient was described as too unstable for repeat CT or surgery. The patient was declared dead less than 24 hours after the fall.

If all the medical and nursing documentation concerning this patient's admission have been provided, then they were clearly inadequate in amount and quality. There was no entry from the neurosurgery registrar involved in the patient's initial assessment, and not even any indication as to whether the neurosurgery registrar personally saw the patient and the CT scans or merely received a verbal account of the patient and the CT results. The only documentation from the ward was two sets of observations taken more than four hours apart and a retrospective entry in the progress notes. Even this limited documentation was poor.



A coroner's autopsy was performed but the result was not available.

Reviewer's comments

Recognition and management of neurological deterioration in this patient was significantly delayed until an irredeemable state had been reached. It is reasonable to suppose that if this had not been the case, the patient may have survived.

The mechanism of injury, the brief loss of consciousness, the evidence of eyebrow laceration/haematoma and CT findings of a subdural haematoma with midline shift in addition to parenchymal bleeding indicate that this patient had a moderately severe closed head injury. Transfer to ED occurred rapidly and this is important when evaluating the clinical condition as there is a well-recognised potential for head injured patients on anticoagulants to have ongoing intracranial bleeding. While neurological observations were initially normal, there was always a significant potential for deterioration.

The area of greatest concern was a significant deterioration in GCS while on a ward without any medical action being taken until it was too late. The normal procedure is for the registrar to be contacted for any fall in GCS of 2 or more points or the development of new neurological deficits such as limb weakness.

The final area of concern is the apparent inadequacy of neurosurgical assessments in the ED and ward.

Subdural haematomas in elderly patients after low velocity injuries are common and there is a tendency to be overly dismissive of them. They are not acutely life-threatening in most cases and it is reasonable not to operate on them at the time of presentation if the patient has no or only mild deficits and is stable. However, elderly patients with acute subdural haematomas must be managed in such a manner that acute deterioration will be recognised and acted upon promptly. This is especially so in the night when the staff on duty may be less experienced and the neurosurgeon or neurosurgical registrar is not on site. Elderly patients with mild or no neurological deficits, operated upon for subdural haematomas, have a reasonable prospect of survival in a good neurological state. Factors that placed this patient at higher risk of deterioration were overlooked, namely the history of anticoagulation (aspirin), the severity of impact, the acuteness of the haemorrhage and the presence of midline shift.



Case 10: Headache plus cerebral aneurysm require urgent treatment

Summary

A patient with a past history of hypertension and hypercholesterolaemia presented to a general practitioner (GP) with unusually severe headaches for a fortnight and with unspecified visual disturbance. The patient was referred to an ophthalmologist, who arranged an MRI of the brain. The MRI demonstrated a large cerebral aneurysm (between 15-25 mm) with mural thrombus. At a follow-up appointment with the GP, a neurology outpatient clinic was arranged for the patient to be seen within a week. The patient then returned home, apparently fell asleep and became unrousable. An ambulance was called and on attendance recorded an initial GCS of 5 with symmetric and reactive pupils. The ambulance officers intubated the patient and issued a trauma call before transportation to a hospital ED. By this time, the left pupil was several millimetres larger than the right. CT of the brain revealed a diffuse subarachnoid haemorrhage with intraventricular blood and early hydrocephalus. The neurosurgery registrar successfully inserted an external ventricular drain in ED and the patient was transferred to ICU where it was noted that the pupils were not reacting to light. The external ventricular drain became blocked by a blood clot and could not be flushed with recombinant tissue plasminogen activator, as suggested by the neurosurgery consultant. A repeat CT of the brain demonstrated further bleeding and more 'mass effect'. The neurosurgery team advised that the patient was to be palliated. When the intracranial pressures rose to the extreme range, no action was taken by ICU.

Reviewer's comments

The quality of the hospital documentation was quite adequate. It would be of interest to read documentation from the GP or the ophthalmologist.

The main concern in this case is why a person with severe headaches, visual disturbance and MRI evidence of a large aneurysm containing mural thrombus was not sent to hospital for urgent admission and management, rather than told to attend an outpatient clinic several days later. Failure to refer the patient to hospital immediately almost certainly cost the patient their life and hence qualifies as an adverse event. Also, I wonder if the patient fell asleep because the GP treated the hypertension that was compensating for the patient's raised intracranial pressure?



There were other issues, such as the time involved in preparing the patient for transport to hospital, time before obtaining a CT and time before inserting an external ventricular drain, each of which might not amount to much when considered separately, but collectively amounted to a delay that could have made the difference between life and death. In a young patient with no significant comorbidity, it could also be debated that urgent clipping or endovascular occlusion of the aneurysm on the night of presentation might have led to a good neurological outcome, as it was clear from the notes that the ultimate deterioration was the result of a rebleed. This was perhaps potentiated by the use of tissue plasminogen activator in the ventricular drain. Many neurosurgery units have a policy of not operating on aneurysms after hours, arguing that the operating conditions are suboptimal and do not favour the patient, but it can equally be argued that some patients will die because of such policies.



Case 11: Poor communication

Summary

An elderly patient with significant medical comorbidities including Parkinson's Disease, diabetes and inflammatory bowel disease underwent a Moore's arthroplasty. Postoperatively, there was a myocardial infarct with APO, however the patient improved and went to rehabilitation where the wound was described as indurated and 'leaking'. The patient was transferred back to the orthopaedic team. The Moore's prosthesis was removed, the wound washed out and the patient transferred to Critical Care Unit (CCU) because of persisting hypotension. Shortly after admission patient developed APO and died.

Reviewer's comments

It seems the decision to reoperate was taken, and the operation performed by an advanced trainee assisted by a basic trainee.

The postoperative management was well described by a senior physician. It seems that the medical team had reservations against surgery and was not involved in the actual decision, but the anaesthetic team did accept the patient for surgery. It was suggested that the anaesthetic team then refused to provide postoperative orders and transferred the patient to CCU without a central venous or arterial line. This high-risk patient was then simply handed over to the medical team to manage.

There was no anaesthetic note or comment regarding the high risk of a fatal outcome. The notes recorded the anaesthetic department's refusal to be involved in the patient's fluid management. Additionally, it seems that the orthopaedic team were not contactable. Quite clearly there was a major problem in communication between the three teams involved in this patient's care.

Another issue was the notes made by the three teams involved in the patient's care. The medical team clearly and concisely wrote a diagnosis and treatment plan. The orthopaedic surgeons and anaesthetists did not provide a similar level of detail.

The patient did not necessarily need to return to the operating room for drainage of their discharging wound. This may be optimal in a well patient, but this patient was febrile, not in pain, had a falling C-reactive protein and was in a parlous state



with cardio-pulmonary problems. I think the decision to operate was made by an inexperienced trainee who was perhaps influenced by rigid treatment protocols.

Conclusions

- Poor interdisciplinary communication.
- There appears to have been poor supervision of the orthopaedic trainee both in terms of the decision taken, the actual surgery and the postoperative management.



Case 12: No apparent plan of management

Summary

A frail, elderly person with a known history of transitional cell carcinoma of the bladder was admitted with acute renal failure and displaying high levels of Creatinine. Comorbidities included chronic obstructive airway disease, diverticular disease and urinary tract infections. There had been a recent cystoscopy prior to admission. There was no information apparent in the notes about events prior to this admission. It was however implied this was muscle invasive disease, although there was no pathology report available.

A CT scan on admission demonstrated bilateral hydronephrosis with an obstructed left system due to a large distal ureteric calculus and obstructed right system of uncertain cause, possibly related to known carcinoma of the bladder. An attempt was made to gain access to both ureters in a retrograde fashion but failed due to technical reasons. It is unclear whether this procedure was performed by a consultant urologist or a trainee. Bilateral nephrostomies and antegrade double-J (JJ) stents were inserted over the subsequent weeks of the patient's admission. The patient ultimately died of multi-organ failure.

Reviewer's comments

The case notes were reasonably adequate. More information about events leading to this admission would have been helpful, such as details of the original cystoscopy and underlying pathology. Most of the doctors' entries into the notes failed to note the time of entry, leading to possible confusion. This is an area which requires improvement. There was no reference to any consultant urologist input throughout the case.

The patient had problems with fluid balance throughout the admission. After the insertion of the right nephrostomy tube, the resident medical staff seemed to fail to understand the significance of the poor urine output through the nephrostomy tube, particularly in the context of a patient with acute renal failure. It was not until two days later that the first medical note was made about this issue. It took nearly a week for this to be addressed with insertion of an antegrade JJ stent.

The residents' assessments and responses to the poor urine output were of variable quality with some being substandard. The fluid charts would suggest that the patient



was in a significant positive fluid balance throughout the admission and this was not commented on.

It was over two weeks after presentation before any attempt was made to relieve the obstruction to the left kidney.

The significant delays between recognising clinical issues and responding appropriately in this frail, elderly patient with multiple comorbidities must almost certainly have contributed to the ultimate demise.

Some examples of areas of concern include:

- Although admitted with acute renal failure and evidence of bilateral ureteric obstruction, it took 48 hours from the time of admission until the original procedure was performed.
- It may have been more advisable to place a nephrostomy tube in the left rather than the right kidney. It is likely this would have been the best option given the history of an obstructing calculus compared with malignant obstruction of the right kidney. No notes were made discussing the rationale for placing a nephrostomy tube in the right kidney initially.
- It took 48 hours for the medical staff to note that the inserted nephrostomy tube was not draining. The implications of this in terms of either a misplaced nephrostomy tube or reflecting poor function was never expressed and possibly not understood by the medical staff. It was not until nearly a week later that an antegrade JJ stent was inserted.
- Most of the notes were made by junior residents, often the covering doctor. There was no clear evidence of consultant urologist input throughout the case.
- When clinical deterioration occurred, no attempt was made to clear the left ureter until nearly three weeks after admission.

The quality of care this patient received was inadequate. Given the considerable comorbidities, there was only ever going to be a short window of opportunity to reverse the processes. It took over two weeks to clear both ureters, by which time multi-organ failure was established and there was little chance of reversal. More timely intervention



may have altered the outcome. There was no documented evidence of consultant urologist input.

These comments must be taken in the context of an elderly patient with multiple comorbidities and possibly an advanced malignancy (although absolute evidence for that was not provided in the notes).



Case 13: Clot retention can lead to death

Summary

This case involves an elderly male who died of a myocardial infarction approximately a few days following an elective transurethral resection of his prostate (TURP). The procedure was delayed for some weeks to gain admission to a hospital with an appropriate level of care for the known cardiac risk factors. The operation report and the preoperative haemoglobin (HB) level were unfortunately not available to the reviewer. The case notes, consisting of entries by resident medical and nursing staff, were adequate to establish a reasonable course of events. The preoperative assessments by resident medical and the anaesthetic staff provided an adequate appraisal of the patient's status.

The patient was diagnosed with clot retention shortly after returning from the operating room. The urology resident attempted to wash out the clots but realised this was incomplete. The size and type of catheter used were not recorded. Nursing notes indicated ongoing pain consistent with clot retention well into the next day. There appeared to be an idea that catheter traction alone would solve the problem.

The patient was then transferred to another ward and hypertension, possibly indicative of persisting pain was recorded, as were frequent catheter blockages.

In the days following the operation, the patient developed chest pain along with a fall in BP and oxygen saturations. A rise in his cardiac enzymes was consistent with a myocardial infarction. A fatal asystolic cardiac arrest occurred that evening.

Reviewer's comments

Postoperative blood loss is difficult to assess without the admission HB level. Painful clot retention may hold a litre of blood. The management of the chest pain has been timely and appropriate with the involvement of the cardiology registrar. The use of aspirin in this circumstance was difficult, but in view of the proven benefit of aspirin in survival from AMI it should probably have been administered. This means that management of any ongoing prostatic bleeding needs to be controlled.

The major area of concern is the failure to resolve the persisting clot retention. Clot retention is dangerous as well as very distressing to patients. Evacuation of almost



all the clots within the bladder is required to stop ongoing prostatic bleeding and the formation of more clots. This may be done by return to the operating theatre and evacuation of the clots by cystoscopy under direct vision. An alternative method is to do a manual bladder washout (vigorous) in the bed. For this to be successful a large bore (22-24 French Gauge (FG) open ended (whistle-tip) catheter is required. A 22 FG Foley-type catheter that is usually inserted post-TURP does not allow adequate extraction of the clots. Therefore a change of catheter may be needed and probably should be done with an introducer to ensure accurate placement; hence a urology registrar needs to be involved. The procedure may take upwards of 40 minutes with the irrigation of several litres of fluid to be sure of removal of all clots. It is probably not a procedure to be delegated to a junior medical staff member without appropriate training and supervision. Once the bladder is free of clots and the return in the syringe is clear, another Foley-type catheter can be inserted and then traction applied to isolate and tamponade bleeding distal to the catheter balloon.

Unfortunately, the post-mortem report made no comment about the presence of clots within the bladder at the time of death.

The definitive management of this patient's postoperative clot retention may have reduced the likelihood of the myocardial infarction. Complete clearance of the bladder clots may have allowed the use of aspirin with more confidence without worsening the prostatic bleeding.



Case 14: Gangrenous bowel after ruptured aortic aneurysm repair

Summary

An elderly patient was admitted to the ED having collapsed unconscious. The patient was described as an obese ex-smoker on aspirin and statin, with low BP, erratic pulse and acidosis. IV adrenaline infusion raised BP to >120 . There was consideration for a pacemaker, chest x-ray and ECHO. Shortly after admission, 'Left lateral abdominal upper pain' was noted and treated by morphine. An ultrasound showed an AAA. BP on adrenaline had again fallen and a limited ECHO showed no tamponade. A CT angiogram showed a ruptured aneurysm. For religious reasons, blood, colloid and gelafusin transfusion were not an option.

At emergency operation a retroperitoneal haematoma was confirmed, and an aortic repair with a Dacron graft, ligation of inferior mesenteric artery and right femoral embolectomy took several hours. On transfer to ICU pH was noted to be outside the normal range. A gangrenous bowel requiring Hartmann's sigmoid colectomy was found at laparotomy. Over the next week the colostomy required two revisions. Despite this, multiple organ failure led to death.

The notifying vascular surgeon classified this case as Australian Society of Anaesthetists (ASA) 4, outcome B.2 ['unexpected but definitely not preventable'], and identified two possible contributing areas of concern: colonic necrosis and inability to transfuse. The first-line assessor queried the ASA 4, delay in ED, and the decision to operate if transfusion was not an option.

Reviewer's comments

- Despite features of bleeding into the left flank, ED did not examine the aorta or arteries below the diaphragm; rather it focused on the chest and in fact exacerbated the aortic bleeding by raising the BP with adrenaline. When abdominal ultrasound gave the diagnosis of aortic aneurysm, despite obesity, it is undesirable to delay another hour for CT and ECHO. Such rupture and shock demanded more prompt clinical diagnosis, urgent surgical consultation and transfer to theatre for repair.



- Patient refusal of homologous blood and blood products must be respected. Outcomes in blood-free elective surgery can be better than those with blood transfusion. In this emergency, the inability to transfuse would certainly impair vital organ perfusion during four operations, as well as the outcome of the patient's postoperative septic and cardiac complications.
- The first operation note included ligation of inferior mesenteric artery (presumably there was back-bleeding by collateral flow) but made no mention of mesenteric pulses or bowel vascularity before closure. There was no estimate of blood loss. By this stage the patient's condition may not have allowed mesenteric artery re-anastomosis. Gut ischaemia is notoriously hard to diagnose after abdominal surgery, but here was acted upon promptly.
- Pressure necrosis of nose, ears and sacrum over a two week period presumably relate to cumulative anaesthetics and prolonged intubations. Gluteal ischaemia may have contributed. Skin breakdown is a source of sepsis in such compromised patients.
- A post-mortem was not done - it would have afforded the surgical team useful feedback on technical aspects of their repair operation. Imaging reports and a letter to the patient's GP were not found in the hospital notes, and it is hoped they were done and sent.

Conclusion

Classical surgical emergencies remain a challenge, requiring prompt recognition in ED and immediate involvement of the surgical team. Had this repair been achieved before such acidosis and vital organ ischaemia developed, survival may well have been possible, though obesity, massive bleeding and then sigmoid gangrene proved insurmountable for this patient. The second-line assessor classified the outcome as 'a' potentially avoidable event with several areas of concern.



List of shortened forms

| | | | |
|------|---|------|---|
| AAA | abdominal aortic aneurysm | LVH | left ventricular hypertrophy |
| AF | atrial fibrillation | LVOT | left ventricular outflow tract |
| AMI | acute mesenteric ischaemia | MET | Medical Emergency Team |
| AMI | acute myocardial infarction | MRI | magnetic resonance imaging |
| APO | acute pulmonary oedema | NICU | Neonatal Intensive Care Unit |
| ARF | acute respiratory failure | PH | pulmonary hypertension |
| ASA | Australian Society of Anaesthetists | PVI | pulmonary vein isolation |
| AVR | aortic valve replacement | SAM | systolic anterior motion |
| BP | blood pressure | TOE | transoesophageal echocardiogram |
| CCF | chronic cardiac failure | TPN | total parenteral nutrition |
| CCU | Critical Care Unit | TURP | transurethral resection of the prostate |
| COAD | chronic obstructive airway disease | VASM | Victorian Audit of Surgical Mortality |
| COPD | chronic obstructive pulmonary disease | VATS | video-assisted thoracoscopy |
| CPAP | continuous positive airway pressure | WBC | white blood cell count |
| CRP | C-reactive protein | | |
| CT | computed tomography | | |
| ECHO | echocardiogram | | |
| ED | Emergency Department | | |
| FAST | Focused Assessment with Sonography for Trauma | | |
| FG | French Gauge | | |
| GCS | Glasgow Coma Score | | |
| GI | gastro intestinal | | |
| GP | General Practitioner | | |
| HB | haemoglobin | | |
| HDU | High Dependency Unit | | |
| ICC | intercostal catheter | | |
| ICU | Intensive Care Unit | | |
| INR | international normalised ratio | | |
| IV | intravenous | | |
| JJ | double-J | | |
| JMO | junior medical officer | | |
| LAA | left atrial appendage | | |
| LFT | liver function test | | |
| LMO | local medical officer | | |
| LV | left ventricle | | |
| LVF | left ventricular failure | | |



Contact details:


Victorian Audit of Surgical Mortality (VASM)
Royal Australasian College Of Surgeons
College of Surgeons' Gardens
250-290 Spring Street
East Melbourne VIC 3002 Australia

Web: www.surgeons.org
Email: vasm@surgeons.org
Telephone: +61 3 9249 1153
Facsimile: +61 3 9249 1130

Postal address:

Victorian Audit of Surgical Mortality (VASM)
GPO Box 2821
Melbourne VIC 3001 Australia

Collaborators:



The information contained in this case note review booklet has been prepared by the Royal Australasian College of Surgeons Victorian Audit of Surgical Mortality Management Committee, which is a declared quality improvement activity. The Australian and New Zealand Audit of Surgical Mortality, including the Victorian Audit of Surgical Mortality, also has protection under the Commonwealth Qualified Privilege Scheme under Part VC of the Health Insurance Act 1973