



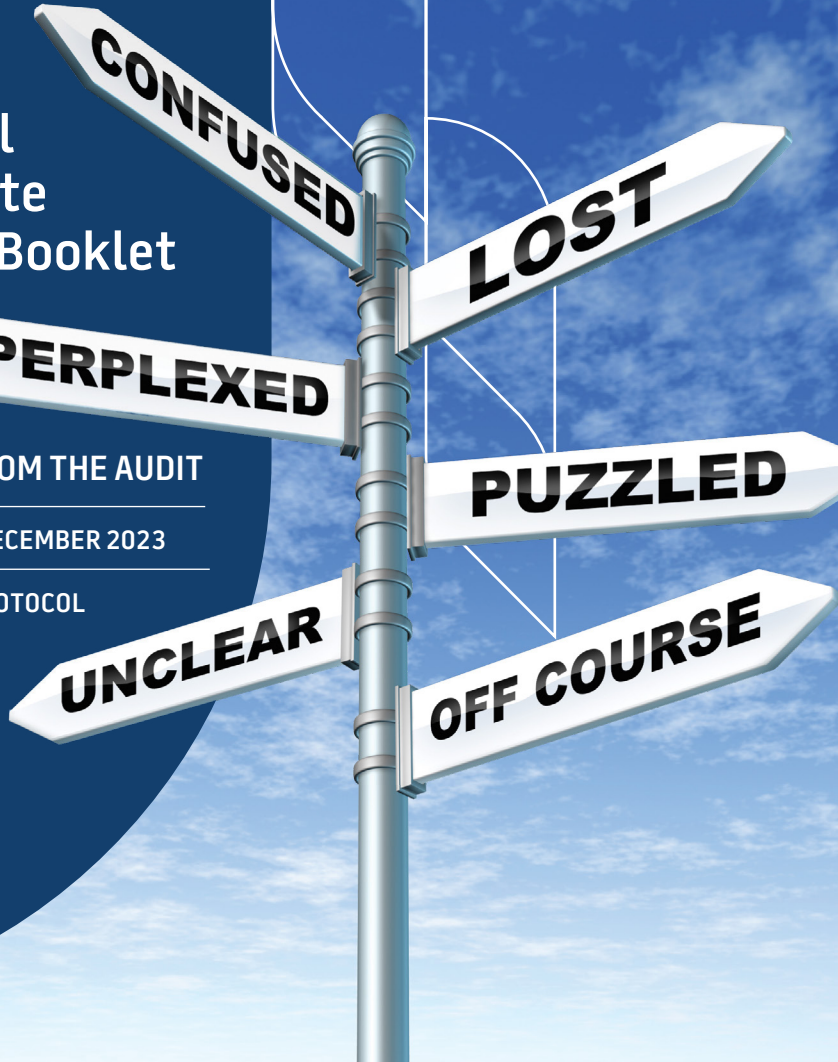
Royal Australasian College of Surgeons  
Australian and New Zealand  
Audits of Surgical Mortality

# National Case Note Review Booklet

LESSONS FROM THE AUDIT

VOLUME 27 | DECEMBER 2023

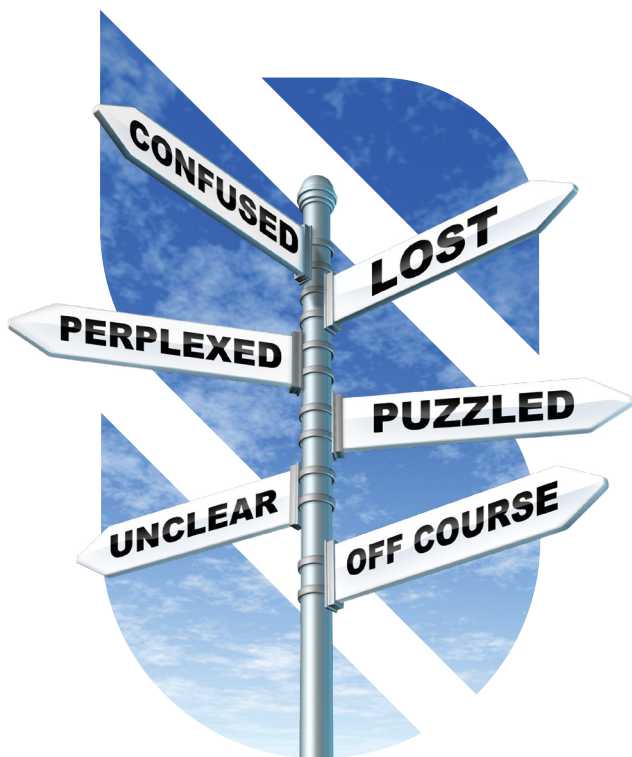TREATMENT PROTOCOL  
ISSUES



Royal Australasian  
College of Surgeons



The Royal Australian  
and New Zealand  
College of Obstetricians  
and Gynaecologists  
*Excellence in Women's Health*



Royal Australasian College of Surgeons  
Australian and New Zealand Audit of Surgical Mortality  
24 King William Street  
Kent Town SA 5067

**Telephone:** +61 8 8219 0901  
**Email:** [anzasm.racs@surgeons.org](mailto:anzasm.racs@surgeons.org)  
**Website:** [www.surgeons.org/anzasm](http://www.surgeons.org/anzasm)

**DISCLAIMER:** This booklet is produced by the Australian and New Zealand Audit of Surgical Mortality (ANZASM), a Quality Assurance initiative of the Royal Australasian College of Surgeons (RACS).

The information contained in this case note review booklet has been prepared on behalf of the Royal Australasian College of Surgeons, Australian and New Zealand Audit of Surgical Mortality. The Australian and New Zealand Audit of Surgical Mortality, including the Western Australian, Tasmanian, South Australian, Australian Capital Territory, Northern Territory, New South Wales, Victorian and Queensland audits of surgical mortality, has protection under the Commonwealth Qualified Privilege Scheme under Part VC of the Health Insurance Act 1973 (gazetted 24 April 2022).

# Contents

Guest Chair's report	2
Case Studies	3
Case 1: Postoperative fluid management again!	3
Case 2: High-risk surgery with inadequate support at a regional hospital	5
Case 3: Multiple preventable delays adversely impact outcome	7
Case 4: Surgical intervention in a patient with an advance care directive	9
Case 5: Trauma emergency – motor vehicle accident involving an oncology patient and airway management	11
Case 6: Conservative treatment versus surgery following a fall	13
Case 7: Earlier intervention may have avoided multiorgan failure after endoscopic retrograde cholangiopancreatography	15
Case 8: Major infection following aortic arch repair	18
Case 9: Financial considerations cause avoidable delay in hospital transfer	20
Case 10: Sepsis due to an infected femoro-distal bypass graft complicated by failed insertion of a subclavian dialysis catheter	22
Case 11: Postoperative cardiac arrest after cholecystectomy in a patient with multiple comorbidities including haemodialysis	24
Case 12: Understanding the benefits of palliative care	27
Case 13: Low-risk surgery does not equate to low-risk anaesthesia	30
Case 14: Delayed diagnosis of ischemic bowel in a patient with stroke-like symptoms	32
Abbreviations	35

# Guest Chair's report

This 27th volume of the National Case Note Review Booklet from the Royal Australasian College of Surgeons continues the well-established tradition of the lessons learned from the Australian and New Zealand Audit of Surgical Mortality under the expert guidance of Professor Guy Maddern. The audit highlights our failures as providers of professional surgical service to our patients. Most of these failures are not caused by complex technical issues but are related to simple oversights in the provision of patient care.

This booklet is essential reading for all junior and senior surgical staff if we are to prevent these common errors. Failure to take a detailed clinical history, to regularly update the clinical notes, to formulate a clear management plan and/or to communicate this with all members of the surgical team appear to be the root cause of many of these errors. Simple measures such as checking serum potassium, performing clotting studies, or undertaking a test trial of an IV infusion of a drug prior to administering the full dose may seem trivial matters in a busy surgical unit, but careful attention to these matters can save lives.

Lack of timely transfer of patients to ICU/HDU or a tertiary-level facility remains a major cause of mortality despite centralisation of some clinical services. Improved use of technology such as continuous monitoring of physiological parameters and adherence to appropriate guidelines should better prepare us for any impending clinical deterioration of our patients. Patient care is a dynamic process prone to errors, not only during surgery but before and after surgery. Booklets such as this reinforce patient-centric care. It is easy to read, with excellent real-life clinical scenarios and lessons to be learned for all those who look after the care of surgical patients.

---

## Professor Jas Samra

Hepatobiliary and Pancreatic Cancer Surgeon

# Case Studies

## Case 1: Postoperative fluid management again!

---

### General Surgery

#### CASE SUMMARY

A 78-year-old woman living at home presented to a regional hospital with abdominal pain and vomiting. A diagnosis of small bowel obstruction secondary to a band adhesion was made by computed tomography (CT) scan on the day of admission. Mixed scarring/consolidation in both lung bases (more on the right side) indicated a repetitive aspiration pneumonia.

At surgery, the laparoscopy—converted to a mini laparotomy—found a band adhesion, which required a small bowel resection with anastomosis.

The patient was appropriately managed in the intensive care unit (ICU) postoperatively. She made good progress and was discharged to the ward on day 2. On day 3, she was passing wind and her abdomen was soft and non-tender. There was minimal aspiration from the nasogastric tube, which was later removed. The patient was supposed to commence on nourishing fluid; however, a routine blood gas showed metabolic acidosis with high chloride. A kidney function test was normal; lactate was normal.

To exclude any anastomotic leak, a CT scan with contrast was organised. Following a consult with the ICU a diagnosis of starvation ketoacidosis was made and the patient was returned to ICU. The dietician recommended commencement on total parenteral nutrition (TPN) but this did not happen. The patient continued to deteriorate slowly in terms of respiratory function. She was intubated on day 5 with increased requirement for inotropic support. It was very difficult for her to be ventilated.

Discussion with the family on day 6 led to cessation of all active treatment. The patient passed away later that day.

#### DISCUSSION

This patient had excellent operative management in a timely fashion with a good outcome leading to resolution of the small bowel obstruction. However, she was failed by poor postoperative management.

The patient was known to have limited respiratory reserve, but there was a delay in the initiation of controlled feeding orally or by TPN. In fear of a refeeding complication her fluid balance was on the positive side by more than 2L every day while she was in the ICU. She was mainly given dextrose.

### **CLINICAL LESSONS**

This patient was failed by poor postoperative management, particularly regarding nutrition and fluid balance. This was an avoidable outcome.

## Case 2: High-risk surgery with inadequate support at a regional hospital

### General Surgery

#### CASE SUMMARY

A frail 85-year-old man was diagnosed with bowel cancer on a background of myeloproliferative disorder, atrial fibrillation (AF) and chronic renal impairment.

The patient had adequate preoperative work-up and was discussed in the multidisciplinary team meeting. He underwent a straightforward right hemicolectomy and was transferred to the ward. A medical emergency team (MET) call occurred a few hours after surgery for low blood pressure, dyspnoea and a haemoglobin drop to 95 g/L; mean arterial pressure at that time was 70 mm Hg. The patient was managed adequately after the MET call. On postoperative day 1 he was transferred to ICU/HDU (high dependency unit) because of concerns. He received a blood transfusion.

A few hours after admission to ICU, the patient was transferred back to the ward. On postoperative day 4, he again had hypotension and AF. He was managed in the ward along with a physician over the course of the following days and briefly transferred again to HDU. He suffered from acute renal injury, ileus and poor intake, and also had chest pain.

In the late evening of day 5, a code blue was called due to hypotension. The surgeon saw the patient and recommended active treatment with fluid resuscitation and antibiotics; escalation to a reoperation or ICU ventilation was not recommended.

Over the course of the next few days, the bowel obstruction/ileus resolved but the patient became weak and refused oral intake. Following a discussion with the patient, palliative care commenced and he died on postoperative day 16.

#### DISCUSSION

This was major colorectal surgery in an 85-year-old man with significant comorbid conditions. Preoperative ICU or HDU should have been organised; however, in reviewing the case notes it appears that this was not arranged. Major surgeries in regional hospitals for patients with comorbid conditions require involvement of ICU prior to surgery. If ICU or HDU care cannot be provided in regional centres, such operations should be done at a tertiary hospital.

An elderly patient with multiple comorbidities should have been kept in ICU for a longer duration. There is no documentation of a postoperative CT scan or imaging to determine the cause of the patient's morbidity. He may have had a leak or postoperative bleed that could have been salvaged with a reoperation. The case notes make it difficult to determine whether reoperative surgery would have been in the best interest of the patient and/or whether this was explained to the patient in detail. In this case, it appears that the patient refused any further management.

### **CLINICAL LESSONS**

Regional hospitals need to be able to fully support high-risk cases.



## Case 3: Multiple preventable delays adversely impact outcome

### Cardiothoracic Surgery

#### CASE SUMMARY

A 46-year-old man presented to tertiary hospital A with dyspnoea, New York Heart Association class 4 symptoms and a lower limb vasculitic rash. He had hypotension, poorly controlled diabetes, anaemia, stage 3 chronic kidney disease, obstructive sleep apnoea and severe ischaemic cardiomyopathy.

Coronary angiography revealed severe triple vessel disease. There was marked global systolic dysfunction. The patient spent 17 days at hospital A before being transferred to tertiary hospital B for coronary bypass surgery. During this time, there was considerable input into the management of the lower limb vasculitis. The patient had occasional ongoing chest pain.

After transfer to hospital B, there was a further 5-day delay before surgery due to more urgent cases and staff shortages. A preoperative intra-aortic balloon pump (IABP) was considered but deemed unnecessary. A coronary artery bypass graft (x3) was performed using the bilateral internal mammary arteries and radial artery. (The vasculitis precluded use of the lower limb saphenous vein; however, the thigh vein was available.) The operative procedure was relatively uneventful although high inotropic support was required in ICU.

A pericardial collection was noted on echocardiogram and an unplanned return to theatre arranged. Unfortunately, there was a delay owing to over-running in theatre and a shortage of theatre staff. During transfer, the patient suffered a cardiac arrest with 8–10 minutes of down time. After reopening, an IABP was placed; however, it became apparent that the patient had sustained a significant hypoxic cerebral event. He died some days later.

#### DISCUSSION

There are several concerns over the management of this patient:

- The vasculitis was never going to be a ‘quick fix’ and given the patient’s precarious cardiac status, the 17-day delay before transfer to hospital B should not have occurred. A further 5-day delay at hospital B added significantly to the potential risk.

- The choice of conduit—all arterial in an obese, diabetic unstable patient—was inappropriate when the thigh vein was available. It was noted at the reopening that the flow in the radial graft was insufficient. It is unclear whether this contributed to the postoperative hypotension but it is an unnecessary added factor.
- Although a preoperative IABP was apparently considered and deemed unnecessary, given the patient’s cardiac status and significant comorbidities, it should have been utilised.
- The delay in return to theatre is completely unacceptable and likely caused/ contributed to the eventual outcome. This should not happen in a relatively high-volume cardiothoracic unit. The cause should be addressed by a root-cause analysis to prevent recurrence.

## CLINICAL LESSONS

There were delays at every stage of this patient’s care. The patient had multiple comorbidities and management was going to be a challenge from the outset. Any adverse event during the perioperative period was likely to adversely affect the outcome.

The initial delay was inordinately long but perhaps the referring hospital had little control despite repeated entreaties to expedite transfer. Whether this delay contributed to the subsequent outcome is uncertain, but it would not have helped.

The causes of the delays at each stage of management, in particular the transfer to theatre, need investigation.

## Case 4: Surgical intervention in a patient with an advance care directive

### General Surgery

#### CASE SUMMARY

An octogenarian nursing-home patient with multiple comorbidities, including thrombocytopenia, autoimmune hepatitis, cirrhosis, heart disease and dementia, presented with a sigmoid volvulus. The patient had an advance care directive stating no ICU, no cardiopulmonary resuscitation (CPR), no intubation and not for intravenous (IV) fluids. The patient was treated successfully with endoscopic decompression and sent home the next day.

The patient re-presented in the evening of the following day with the same complaint. The advance care directive was again noted, and a discussion was undertaken in the emergency department (ED) between the patient, their partner, the senior ED doctor and surgical registrar, concluding that a laparotomy would not be in the patient's best interest. It was considered that there was a substantial risk of complications due to the patient's multiple comorbidities, a possible prolonged ICU recovery and high likelihood of non-survival. The patient and partner agreed with the outcome of the discussion and the proposal to await the morning team review, with a view to repeating the endoscopic decompression as the established ceiling of care.

The next morning, however, a discussion between the surgical team, ICU and the patient's family noted that despite the risk of high morbidity and mortality and poor quality of life, the family decided to proceed to surgery with a focus on preoperative optimisation. A preoperative haematology consultation occurred for the low blood platelet level ( $47 \times 10^9/L$ ). The advice was that the patient was a poor surgical candidate. Suggested pre- and postoperative management of the patient's coagulation profile was provided, including a resuscitation plan. The mortality risk for abdominal surgery in this patient (Child–Pugh A score for cirrhosis) was 10%. Given the patient's poor functional status with likely poor reserve, the risk of mortality was likely much higher.

A laparotomy and on-table lavage, adhesiolysis, sigmoid colectomy and end colostomy was performed that afternoon during a 3-hour operation.

On postoperative day 2, the patient suffered a non-ST-segment elevation myocardial infarction (NSTEMI) followed by acute pulmonary oedema and intra-abdominal bleeding. On postoperative day 3 the patient developed multiorgan failure and was transitioned to palliative care. The patient died 28 days after surgery.

## DISCUSSION

Endoscopic decompression upon the initial presentation was appropriate treatment, enabling the patient to return to the nursing home the next day. However, consideration may have been given to keeping the rectal tube in for longer duration to facilitate established oral intake and bowel function and thus mitigate the risk of early re-presentation. When re-presentation occurred, it is unclear why endoscopic decompression was not repeated as suggested.

The operation itself was unusual. Even though this ended up being a Hartman's resection, the need for on-table colonic lavage is not clear; presumably there was thought of performing a primary anastomosis, although this too, is unclear. The indication to operate emergently on such a poor surgical candidate is also not strong. There was no evidence of ischaemia, perforation or sepsis. It seems that the only indication to operate was to prevent recurrence.

An important factor was the decision to operate at all. This was an elderly patient with multiple comorbidities and poor quality of life with an advance care directive, which was presumably in place to prevent these types of situations. From review of the notes available, it is very clear that every doctor involved in this patient's care was of the same opinion: that this patient would likely do poorly from surgery. Despite this medical opinion, the documentation seems to suggest that it was the family that expressed the desire for surgical intervention.

## CLINICAL LESSONS

The decision to operate falls on medical practitioners and in particular, the surgeon. Often, relatives will pursue surgical interventions when given the option, to feel that they did everything they could. When the intervention fails and the patient lingers in hospital until death, as in this case, they will often feel guilty about this decision.

The family should not have been given the option of surgery, as it was not a realistic option. Instead, at a family discussion and with medical consensus, the discussion should have gone something like this: 'We are all of the opinion that anything more than endoscopic decompression will be futile and likely cause the death of your family member. As such, this will not be offered.'

Reference should also be made to the established advance care directive in these family discussions, to highlight acceptable care parameters. This helps prevent the situation of surgical intervention contrary to the care standards agreed to within that document and non-adherence to related protocols and criteria.

# Case 5: Trauma emergency – motor vehicle accident involving an oncology patient and airway management

---

## General Surgery

### CASE SUMMARY

A patient age early-50s was the driver in a single vehicle car accident. The victim self-extricated and was conscious and alert when ambulance officers arrived but became quite agitated en route to hospital and challenging to manage. The patient was admitted to the ED with an isolated head injury with deep laceration and depressed skull fracture. No other significant intracranial injury was noted. The patient had a mild intellectual disability and type 2 diabetes, was a smoker with hypercholesterolaemia and known laryngeal cancer having (presumed) chemoradiation and was on warfarin.

An immediate CT scan indicated significant progression of the cancer with poor tracheal patency at C6. The patient evidently had stridor and respiratory failure due to airway compromise from the tumour. Oxygen saturation fluctuated between the high-80s and high-90s. The patient was more settled when able to sit upright and have more control of the situation. Neurosurgery review was planned along with ICU admission.

The surgical registrar advised the consultant of the trauma patient approximately 2 hours after admission. The ICU and ED teams conferred at this time and decided not to attempt to secure the airway. The patient was noted as high-risk for falls due to repeatedly slumping forward when sitting in a chair; however, the patient was able to walk around the department without issue. There were concerns about intermittent agitation.

The patient was transferred to ICU, requiring oxygen en route, escalating to 100% on arrival. Oxygen saturation fluctuated continuously for 45 minutes before rapid deterioration and hypoxic cardiac arrest. Attempts at intubation and tracheostomy failed. CPR was unsuccessful. The patient was pronounced dead 5 hours after ED admission.

### DISCUSSION

This very challenging case highlights the difficulties of decision-making in a major trauma in a regional setting, combined with tonsillar cancer-related airway compromise and obesity. The ambulance service had difficulties during transfer to the base hospital due to the level of agitation of the patient. Due to

the pre-existing airway obstruction (tumour) and body habitus, the patient was transported in a semi-sitting position.

This scenario would challenge any trauma centre to start with, but clearly no quality diagnostics and survival can be expected without a secured airway in a hypoxic, periodically desaturating patient with depressed skull fracture and associated traumatic brain injury. The decision not to secure the patient's airway could be reasonable in a palliative context, with the agreement of the patient and family wishes, but is unlikely to have any positive outcome if active treatment is considered. The airway situation was not discussed by the ED or ICU teams or the anaesthetic consultant on call.

If this was addressed as a matter of urgency during the early stages of admission, the patient may have survived.

Optimal management could have been endotracheal intubation with the best available medical and equipment resources and all back-up options available including surgical airway. Depending on the institution, this could happen in the ED, the ICU or in the operating theatre by specialties with advanced airway management skills. Once the secure airway was established and complete diagnostic imaging performed, the local surgical team and a consulting neurosurgeon from a major trauma centre, together with critical care physicians and family, could have decided the best management plan for the patient in the context of the injuries and malignancy-associated life expectancy.

## CLINICAL LESSONS

This patient should have been transferred to a tertiary facility with neurosurgical services before deteriorating. The airway should have been risk-assessed as early as possible following presentation to the ED and managed appropriately. Implementation of the general airway checklist may have facilitated access to higher-level care.

## ANZASM COMMENT

It is not uncommon that ignoring well-established basics can be costly, therefore sticking to basics is vital.

In general terms, and particularly in trauma, securing the airway is the first and utmost priority. In the presence of compounding factors like obesity, throat infections or tumours, securing the airway gains even higher priority.

In critical situations, pre-emptive actions can be crucial. When a window of opportunity is offered, it should be utilised to the full.

## Case 6: Conservative treatment versus surgery following a fall

### Spinal Surgery

#### CASE SUMMARY

An 81-year-old man who lived alone was admitted to hospital following a fall with a period of unconsciousness. He reported neck pain as a new problem. There was no relevant medical history other than alcohol abuse (1 L of wine per day). A cervical spine X-ray showed a C2 ‘hangman’s fracture’. The patient was noted to be neurologically intact, had good head control and was initially planned for conservative management.

A CT scan of the cervical spine showed bilateral fractures of the C2 lateral masses with anterior translation and rotation, with fractures extending to the surface of the C1/2 articular facet. Both fractures extended through the transverse foramen. The patient was treated with a sternal occipital mandibular immobiliser (SOMI) brace. The following day he was noted to be agitated and subsequently disorientated. On day 2 of admission, his images were reviewed at a spinal unit consultant meeting and a CT angiography (CTA) was recommended. The patient was confused and had a spiking temperature up to 39 degrees. Aspirin was started.

A speech pathology review felt there was a high aspiration risk given the positioning restrictions and the head held in extension. Enteral nutrition was recommended. By day 3 of admission, he had developed either a pressure sore or laceration on his occiput. Surgical treatment was discussed since it was felt the fracture was unstable. From that time on the patient’s conscious state was variable. He was agitated, and subject to a nurse to awaken him regularly. It was felt the agitation was secondary to alcohol withdrawal. The nasoenteric feed was problematic, as were his electrolytes. Aspirin was changed to enoxaparin in preparation for theatre.

On day 7 of admission a full medical review was performed. It was felt that the fall and a concussion, alcohol withdrawal, communication problems and hearing impairment, and possible infection had all contributed to the patient’s multifactorial delirium. He was subsequently seen by the geriatric team. A holistic medical plan with a stimulation environment and respiratory care was planned in addition to pain control.

On day 10 of admission the patient went to theatre for an anterior cervical fusion. The surgical result was good and he was subsequently nursed in ICU. He remained intubated and ventilated initially; subsequent decline was due to respiratory failure. His eventual death occurred 26 days into his admission.

## DISCUSSION

This was a difficult situation with an elderly man not ideally placed for conservative treatment of a displaced fracture, who subsequently underwent surgery. The operation achieved a good result in terms of reduction of the fracture and fusion.

The holistic nature of this patient's care in hospital deserves comment. There were no notes from the medical staff detailing any conversations with the family. The first time there was a review with the geriatric team was one week into admission. By this time the patient was already in some respiratory distress and agitated.

From a surgical and orthopaedic viewpoint there are no areas of concern other than that the operation may have been beneficial if done earlier. In retrospect, once it was decided surgical intervention was required due to the instability of the fracture, this should have been performed earlier to avoid a week in a SOMI collar and development of other complications.

Discussions with the family appear to be lacking (as judged by the notes) and there appears to have been late recognition that an 81-year-old drinking a litre of wine per day is medically fragile and requires geriatrician support.

## CLINICAL LESSONS

This case highlights the value that early geriatric input can have in achieving the best possible outcomes for patients. An opportunity was potentially missed due to the delay in engaging geriatrician support.



# Case 7: Earlier intervention may have avoided multiorgan failure after endoscopic retrograde cholangiopancreatography

## General Surgery

### CASE SUMMARY

A 73-year-old woman living independently was referred to the ED with a 2-week history of right-side abdominal pain. A recent CT scan was negative and there was no significant medical history. The patient was investigated with renal ultrasound and CT-pulmonary angiogram, both of which were normal. Magnetic resonance cholangiopancreatography on day 8 of admission demonstrated a stone (17.7 x 4 mm) in the common bile duct (CBD).

Endoscopic retrograde cholangiopancreatography (ERCP) was performed by a gastroenterologist on day 9 of admission, which confirmed choledocholithiasis with an 18-mm stone. An endoscopic sphincterotomy was performed and the stone was extracted with difficulty. A stent was placed in the pancreatic duct for prophylactic drainage. Record-keeping following this procedure was very poor with no record of further review or input by the gastroenterologist. The patient developed what was felt to be post-ERCP pancreatitis, confirmed by elevated amylase and lipase on day 10 of admission. This was initially treated with IV hydration and analgesia. However, a CT scan on day 12 of admission demonstrated a large retroperitoneal haematoma, severe pancreatitis and the possibility of the stent outside the duodenum. This finding would be consistent with an injury to the duodenum caused by the sphincterotomy during ERCP.

The patient was resuscitated in ICU and underwent an urgent laparotomy. The retroperitoneal haematoma was drained, the bleeding transverse mesocolic vein was ligated, and the necrotic superior mesenteric vein was resected with revascularisation achieved by primary anastomosis. As the patient was unstable, the abdomen was left open. The patient was managed in ICU with inotropic support. After a week of slow improvement, she was taken back to theatre on day 25 of admission for abdominal closure.

The patient initially improved, with 2 large retroperitoneal drains for the pancreatitis, a tracheostomy and nasogastric feeding. Unfortunately, the patient developed a wound breakdown from infection, which was treated with IV antibiotics and vacuum-assisted closure dressing. A slow improvement occurred in ICU; however, after about 4 weeks, the patient developed retroperitoneal bleeding with blood oozing from the retroperitoneal drains. A multidisciplinary

discussion between the radiologist, intensivists, the surgeon and the patient's family concluded that surgical intervention was the most appropriate treatment.

On day 53 of admission, laparotomy access was difficult with no peritoneal space accessible. Instead, the drains were changed and biological glue was injected to try to stop the bleeding. This was unsuccessful. The patient exsanguinated and died on day 57 of admission.

## DISCUSSION

There were a number of major adverse events in the management of this elderly patient who was investigated and finally diagnosed with choledocholithiasis. The initial CT scan did not demonstrate the CBD stones and there was no comment about duct dilatation. Liver function tests were mildly abnormal, with gamma-glutamyl transferase 87 IU/L (normal range 5–35 IU/L) and lactate dehydrogenase 278 IU/L (normal range 120–250 IU/L); bilirubin, aspartate transaminase and alanine transaminase were within normal range. Appropriate treatment for extraction of the CBD stones by ERCP was provided, but in the course of this a duodenal perforation and likely vascular injury to the junction of the superior mesenteric and middle colic vein were caused. The severity of this injury was not appreciated at the time. Subsequently, the care the patient received is poorly recorded and there appears to be no further assessment by the gastroenterologist responsible for the ERCP.

The patient developed post-ERCP pancreatitis as a result of this injury. This can occur in 3–5% of post-ERCP patients. Severe pancreatitis has been reported in 0.3–0.5% of cases. Risk factors for severe post-ERCP pancreatitis include endoscopist inexperience, sphincter of Oddi dysfunction, difficult cannulation, and performing a therapeutic rather than diagnostic ERCP.<sup>1</sup> This patient had the risk factors of a difficult procedure and performance of a therapeutic procedure.

The pathogenesis of acute pancreatitis has been attributed to transient obstruction of the common bile and pancreatic ducts, which causes reflux of bile and duodenal content in the pancreatic duct and/or increases the hydrostatic pressure in the pancreatic duct.<sup>2</sup> In this instance, the aetiology appears to be the result of direct pancreatic trauma during sphincterotomy. Pancreatic necrosis develops more often when the duration of obstruction exceeds 48 hours. The obstruction may be constant—due to an impacted stone—or intermittent, such as when a stone remains in the bile duct or multiple stones try to pass the ampulla.

This patient developed the features of severe haemorrhagic pancreatitis, defined as acute inflammation and necrosis of pancreas parenchyma, focal enzymic necrosis of pancreatic fat and vessel necrosis (haemorrhage). Severe acute pancreatitis is defined by single or multiple organ failure lasting more than 48 hours and is associated with a mortality rate as high as 25%.<sup>3</sup>

The patient was managed appropriately in ICU with inotropic support, nasogastric feeding and a repeat laparotomy for necrosectomy and drainage. When the patient developed further intra-abdominal bleeding—most likely due to advancing pancreatic necrosis and from peripancreatic tissue and surrounding vessels—the laparotomy on day 53 of admission was unable to be performed due to lack of peritoneal space, and the patient exsanguinated.

## CLINICAL LESSONS

1. ERCP should be done by experienced endoscopists who can identify complications at the time of the procedure.
2. Removal of a large stone through the ampulla is fraught with danger. Consideration should have been given to crushing the stone into smaller bits for removal.
3. The potential complications of ERCP rise exponentially in elderly, diabetic patients with large stones, and with inexperienced endoscopists.
4. The surgeon or gastroenterologist performing ERCP has a duty to follow-up the patient to ensure they are making a smooth recovery.
5. Comprehensive documentation is essential to patient care. Lengthy gaps in the medical record complicate subsequent care and compromise patient safety.
6. Most hepatobiliary units have shown that laparoscopic exploration of the CBD and primary closure is safe, even if the stones are large. Techniques of stone destruction using ultrasonic, laser and crushing forceps would have been an option. Referral to a surgeon with experience in this field should be considered.

## REFERENCES

1. <https://www.uptodate.com/contents/post-endoscopic-retrograde-cholangiopancreatography-ercp-pancreatitis>
2. Biliary pancreatitis: a review. Emphasizing appropriate endoscopic intervention. Frakes JT, J Clin Gastroenterol. 1999 Mar; 28(2):97–109.
3. Banks PA, Bollen TL, Dervenis C, et al. Classification of acute pancreatitis—2012: revision of the Atlanta classification and definitions by international consensus. Gut. 2013;62:102–111.

## Case 8: Major infection following aortic arch repair

### Cardiothoracic Surgery

#### CASE SUMMARY

A 72-year-old man was admitted for elective repair of an aortic arch aneurysm with progressive de-branching. Relevant medical background included an aortic arch stenosis 9 months prior to surgery for central chest pain resulting in multiple ED admissions, previous myocardial infarction, hypertension, type 2 diabetes mellitus, chronic obstructive pulmonary disease (COPD), benign prostatic hyperplasia and a previous laparoscopic cholecystectomy.

The patient was discharged from ICU 3 days after surgery. A MET call occurred the first night on the ward and a further MET call the following day due to shortness of breath and hypotension. On postoperative day 6, the patient was diagnosed with left laryngeal nerve palsy. On postoperative day 10 the patient had strong retrosternal pain with leukocytosis. IV antibiotics were started. The sternal wound was noted for the first time. The patient underwent exploratory sternotomy for a retro-sternal collection and was readmitted to ICU for respiratory distress, fever, rigors and need for endotracheal intubation. By day 11 following the initial surgery, the patient could not awaken appropriately; a CT scan showed a large ischaemic stroke. The infectious organism *Staphylococcus epidermidis* was isolated from blood cultures.

After a series of family meetings, the decision was made to provide palliative care. The patient died 14 days after the initial surgery.

#### DISCUSSION

The surgeon described thrombosis of the extra-anatomical debranching great vessel conduit as the cause of the patient's profound stroke. This would be a rare complication and its coincidence with staphylococcal mediastinitis seems unusual. Gross contamination of the surgical field or IV lines could explain early infection of the grafts with intra-luminal vegetation, stroke and mediastinitis. (All surgery consumables were within the best-before date. Instrument trays and the Intergard Woven graft [D 10 mm/L 30 cm, ref IGW0010-30, Lot: 18J06, SN: 1182214622] had no labelled use-by dates.)

Much of the documentation was insufficient:

- Preoperative documentation by the surgeon was limited to a letter, which failed to discuss indication for surgery or the patient's special needs including social work.

- The patient did not speak English and it was not documented if an interpreter was used.
- The surgeon's notes did not resolve mixed information from the medical team as to whether the cause for surgery was type B dissection, pseudo-aneurysm, chest pain or elective surgery as planned.
- The medical records did not mention use of antibiotic prophylaxis of the surgical wound, which was critically important in this case.
- The operation report did not include myocardial protection (this information had to be found in perfusion records) or convey in what state the patient was transferred to ICU (with a bleeding disorder, needing inotropes etc.).
- The anaesthetic and perfusion reports specified progression and times of clamping and reported right ventricle failure at the end of the case.
- Nursing documentation did not show use-by dates on instrument trays. This should be addressed with internal governance for future rectification.
- Radiology, pathology and cardiology images and reports were not provided.

In terms of what went well, multidisciplinary team meetings were favourable for spreading knowledge and team-building. Cardiothoracic and vascular surgery cooperation extended to the operative field and appeared to be very positive. Although documentation was incomplete and the patient ultimately perished from major surgical infection, the flow of the procedure appeared reasonable for such a large operation, including good surgical strategy accomplished within an appropriate timeframe.

In terms of what could improve, the patient succumbed to an early systemic infection caused by a skin microorganism. It must be assumed that gross surgical contamination occurred. Other possibilities are introduction of microorganisms by IV lines or extra-corporeal equipment. It is unfortunate that such a complex surgery was well executed, but the patient died of surgical infection.

## CLINICAL LESSONS

This case presents an opportunity for clinical teams including surgery, anaesthesia, nursing, ICU and infectious disease (or the hospital infection committee) to review its practices and policies.

Surgical infection can happen; however, it is incumbent on the surgeon to try and prevent occurrence of these events. In this case, it was recommended that the surgeon meet with the hospital infection committee and review its policies. All teams involved in the care of the surgical patient need to be involved and it shows good leadership if the process is driven by the surgeon.

## Case 9: Financial considerations cause avoidable delay in hospital transfer

### General Surgery

#### CASE SUMMARY

A man age 46 was admitted to a regional hospital with type 1 respiratory failure due to disseminated tuberculosis. On day 3 of admission a CT scan of the abdomen revealed extensive free gas indicative of a visceral perforation. He subsequently developed bilateral pulmonary emboli and acute renal failure.

A decision for transfer to a metropolitan tertiary centre was contemplated, but this was not actioned until 9 days after admission. A laparotomy at the tertiary centre was performed 3 days after transfer, whereby a segment of perforated jejunum was identified and damage-control surgery was performed.

The patient was returned to theatre for restorative surgery 3 days after the index operation, but he continued to decline. On day 22 a decision was made for palliation, following the diagnosis of a hypoxic brain injury with poor prognosis.

#### DISCUSSION

The main issue of concern is that this patient was found to have extensive free gas on CT scan on day 3 indicative of a perforated viscus. Given the complexities of his presentation to a regional centre, transfer to a metropolitan tertiary centre for further management was contemplated; however, this seems to have been decided against by the treating team at the tertiary centre on the grounds that it was 'costly' (it is unclear if the patient had a Medicare number given his international status) and would be futile given the patient's overall high risk. It is concerning that despite the degree of free gas, the surgical team on day 7 was hopeful that conservative treatment would lead to spontaneous closure of the visceral perforation despite clear signs that the patient was continuing to deteriorate.

It is clear that resources at the regional centre were inadequate to manage this patient even if there was no perforation, as he had disseminated tuberculosis and would have benefited from specialist infectious diseases input unlikely to be available there. The requirement for continuous renal replacement therapy in light of his acute renal injury from the sepsis and pulmonary embolism also made ongoing management at the regional centre very challenging.

Once the patient had been transferred to the metropolitan tertiary centre, it is unclear why it took a further 72 hours before the patient reached the operating theatre for source control.

This patient was high-risk and complex; however, there was a significant delay in his surgical management for a perforated viscus, despite ongoing deterioration. The patient may have benefited from an earlier laparotomy and if this was unable to be performed at the regional centre, he ought to have been promptly transferred to the metropolitan tertiary hospital. There appears to have been no communication between the 2 hospitals prior to the transfer. Perhaps early senior-level input may have concluded that an earlier transfer was warranted regardless of any administrative or financial issues.

This case raises the following areas of concern:

- questionable decision-making for a conservative approach towards a perforated viscus for a patient with overwhelming sepsis requiring urgent surgical source control
- delay in transfer to an appropriate metropolitan tertiary service
- lack of communication between the hospitals and collegial senior input.

The following recommendations are advised:

- The patient ought to have been transferred early in light of his complex medical issues.
- Transfer should have been done at least when the CT scan revealed evidence of a visceral perforation.
- If a conservative approach was preferred, this should have been done in direct consultation with senior medical input at the metropolitan tertiary centre, with a low threshold for transfer if there was ongoing clinical deterioration.

## CLINICAL LESSONS

This patient ought to have been transferred earlier to the metropolitan tertiary centre with any financial issues left for administrators to resolve. A decision not to transfer driven by financial considerations is wholly inappropriate. The overriding and paramount duty is towards patient safety and quality care.

# Case 10: Sepsis due to an infected femoro-distal bypass graft complicated by failed insertion of a subclavian dialysis catheter

## Vascular Surgery

### CASE SUMMARY

An 82-year-old man presented with severe septic complications from an infected femoro-distal bypass graft. Despite adequate and timely surgical interventions, ICU support and antibiotic treatment the sepsis was never fully controlled. His general condition gradually deteriorated, requiring readmission to ICU.

In ICU his condition progressed towards multiorgan failure with an unfavourable outcome highly likely. The patient's demise was accelerated by a serious complication arising from a failed attempt to insert a subclavian dialysis catheter (Vascath). A successful needle puncture detected relatively high-pressure back flow through the needle; it was regarded as venous blood. Blood gases were requested but the results were not documented in the patient notes.

Guide wire insertion then followed without ultrasound guidance. The proceduralist encountered difficulties in manipulating and advancing the wire initially. The Vascath was then inserted over the guide wire. There are no notes regarding whether the catheter was tested at the completion of the procedure as to whether venous blood was freely aspirated. A post-procedural chest X ray—not read by a radiologist—showed an 'acceptable' anatomical position of the catheter.

One hour after catheter insertion it became obvious that saline flush through the catheter caused chest pain. Aspiration of blood from the catheter was not possible. A comprehensive entry at this point by the ICU registrar (who did not perform the procedure) detailed these events. The registrar initiated further diagnostic studies. The likelihood of vascular trauma was also raised. The subsequent contrast CT scan examination described a misplaced central catheter (Vascath) positioned fully in extravascular position. The CT scan also confirmed continuous patency of the subclavian vessels without apparent contrast extravasation, indicative of active bleeding. Due to the fact that the patient had remained haemodynamically stable, an acceptable decision was made to delay removal of the Vascath until the following morning. It was planned to replace the Vascath using a different access site.

In the morning the subclavian Vascath was removed in the ICU, immediately followed by uncontrollable haemorrhage into the left hemi-thorax. The patient



was intubated, resuscitated and transferred to the angiography suite where wire and catheter access to the left subclavian artery was established without delay. The intraprocedural angiography revealed active bleeding through the traumatised wall of the subclavian artery. It is most likely that before removal of the Vascath the bleeding site was externally sealed by the adjacent misplaced catheter.

Routine insertion of a 'covered' stent into the traumatised subclavian artery immediately controlled the haemorrhage and the patient's haemodynamic parameters improved. However, by that time, an unfavorable outcome was inevitable.

## DISCUSSION

Of the several available access site options, blind insertion of a subclavian dialysis catheter (Vascath) was chosen. The subclavian access, although not favoured by many, remains an acceptable approach in highly experienced hands.

Without adequate ultrasound guidance it is difficult to check the intravascular position of the guide wire/catheter, making the procedure challenging. One also has to be aware of the difficult anatomy of the thoracic outlet, which renders manual compression for controlling haemorrhage from iatrogenic arterial injury difficult if not impossible.

The lack of preparedness for managing a suspected iatrogenic arterial injury is another important factor. Early utilisation of the angiography suite would have provided wire access for endovascular repair and immediate control of the subclavian artery bleeding site.

## CLINICAL LESSONS

Insertion of a central catheter (Vascath) should follow a set protocol.

Testing the patency of the IV line is mandatory at the completion of the procedure. Pressure measurements and blood gas studies are recommended to exclude arterial placement of the catheter. If patency is questionable, one must consider that misplacement of the catheter is likely, with or without vascular trauma.

If in doubt regarding the position of the catheter, it is recommended to seek early advice from a radiologist for appropriate imaging and interpretation. Close supervision is strongly suggested for inexperienced operators.

In case of suspected arterial trauma, consider utilising the facilities of the angiography suite (hybrid lab). Sole reliance on manual compression of the subclavian access site is best avoided.

# Case 11: Postoperative cardiac arrest after cholecystectomy in a patient with multiple comorbidities including haemodialysis

## General Surgery

### CASE SUMMARY

A 38-year-old man was transferred from rehabilitation to surgical care 13 weeks after percutaneous cholecystostomy for further treatment of ongoing acute cholecystitis. The patient was in rehabilitation after a below knee amputation. Other significant comorbidities included end stage renal failure on haemodialysis, insulin dependent diabetes mellitus, ischaemic heart disease with previous left ventricular ejection fraction of 20–25% (increased to 52% seven months prior to death).

Following the percutaneous cholecystostomy, the rehabilitation physicians were concerned about the patient's lack of progress and advocated for a cholecystectomy. Hence, 13 weeks after the cholecystostomy, the patient proceeded to semi-elective laparoscopic subtotal cholecystectomy.

Preoperative haemoglobin was 112 g/L; potassium levels were 4.0 mmol/L and 4.7 mmol/L one week prior to surgery. The operation duration was 168 minutes. The case notes document use in theatre of 'SCDs/IPC's' (sequential compression device or intermittent pneumatic compression). Intraoperative excess blood loss was estimated at 700 ml. One unit of packed red cells was transfused at the end of the procedure; haemoglobin was 80 g/L. The following day, haemoglobin was 82 g/L and there was no evidence of any blood loss after the operation.

Overnight and on postoperative day 1, the patient was borderline hypotensive; potassium was 4.7 mmol/L. Review by the renal consultant prior to haemodialysis recommended a 250 ml fluid bolus, which resolved the hypotension.

At nursing handover 36 hours after the operation the patient was noted to be well, but 3 hours later he was found unresponsive and without a pulse. CPR and a MET call were initiated. Throughout resuscitation, he had pulseless electrical cardiac activity. The resuscitation team documented concerns for possible hyperkalaemia and hypovolaemia (given the previous hypotension). The team also documented the need for blood transfusion, although haemoglobin was 85 g/L during resuscitation.

During resuscitation, blood gas potassium was recorded at 6.6 mmol/L and 7.3 mmol/L on laboratory testing. After 20 minutes of aggressive resuscitation,

including IV measures to address likely hyperkalaemia, three medical staff concluded that resuscitation was ‘medically futile’. It is likely the patient had been pulseless for some time.

## DISCUSSION

There was a lack of documentation by the surgical team. The decision-making process leading to cholecystectomy could not be clearly ascertained. However, given that the patient only proceeded to cholecystectomy 13 weeks after the failed management by percutaneous cholecystostomy, it is apparent that the surgical team did not rush into an operation without ample time to consider treatment options.

While it is difficult to tell from the notes, there is little evidence of any preoperative assessment by renal, cardiac or intensive care physicians. Apart from the standard preanaesthetic review performed the day prior to surgery by an anaesthetic registrar, the only documentation in the notes of the potential risks of surgery was in the consent form signed by an intern. This form has generic text stating: ‘General Risks. Death as a result of this procedure is possible.’ In the section of the form concerning ‘risks of not having this procedure’, the intern documented: ‘ongoing symptoms.’

The American College of Surgeons NSQIP (National Surgical Quality Improvement Program) surgical risk calculator estimated a 9.1% risk of serious postoperative complications for this patient. Such a high risk justifies perioperative management in a critical care unit. Although no drain cholangiogram was performed preoperatively, this would not have changed management. The literature reports that the median duration of surgery for a difficult cholecystectomy is 60 minutes (range 25 to 120 minutes), and 43 minutes (range 15 to 135 minutes) for a less difficult cholecystectomy.<sup>1</sup> However, two hours in this instance for what was described as a difficult cholecystectomy with intraoperative haemorrhage needing transfusion still seems short.

## CLINICAL LESSONS

Death appears likely from hyperkalaemia and cardiac arrhythmia, which was not detected for some time on the ward. A monitored bed and more intensive electrolyte monitoring, even a day-and-a-half (39 hours) following surgery, would potentially have been lifesaving.

Closer perioperative management by cardiology and renal physicians plus preoperative review by intensivists should have been undertaken, and admission to a critical care unit should have been considered.

## REFERENCE

1. Reinders JS, Gouma DJ, Heisterkamp J, Tromp E, van Ramshorst B, Boerma D. Laparoscopic cholecystectomy is more difficult after a previous endoscopic retrograde cholangiography. *HPB (Oxford)*. 2013 Mar;15(3):230-234. doi: 10.1111/j.1477-2574.2012.00582.x.

## Case 12: Understanding the benefits of palliative care

### General Surgery

#### CASE SUMMARY

A 75-year-old man was admitted from a nursing home with abdominal pain, weight loss and acute-on-chronic back pain. The patient had multiple comorbidities including AF, vascular cognitive impairment, heart failure, obesity, type 2 diabetes mellitus, hypertension, chronic kidney disease (stage 3), peripheral vascular disease, COPD, liver cirrhosis (Child–Pugh score A), chronic left lymphoedema with recurrent cellulitis, previous non-Hodgkin lymphoma and previous hepatocellular carcinoma (treated with stereotactic body radiotherapy, 2020).

On admission, the CT abdomen was reported as normal. The patient's pain worsened over the next 3 days and a repeat CT scan suggested loop of abnormal bowel with mesenteric stranding and possible extraluminal gas. His white cell count (WCC) was  $23 \times 10^9/\text{L}$  and lactate was 2.5 mmol/L. The patient proceeded to laparotomy and a 30-cm segment of ischaemic small bowel 15 cm proximal to the ileo-caecal valve was removed. Laparostomy was performed, and the patient returned to theatre 48 hours later for inspection of the bowel, anastomosis and closure of the abdomen. Recovery was complicated by a liver abscess; however, the patient recovered and was discharged on postoperative day 57.

The patient presented to a different hospital 41 days later with generalised abdominal pain that had been present since the abdominal surgery but had worsened over the previous 3 days. He had associated nausea, vomiting, anorexia, lethargy and diarrhoea.

The patient was assessed by a surgical registrar who concluded the patient did not have acute abdomen but possibly ileus related to electrolyte derangement from poor oral intake. A CT was suggestive of ileus (no other pathological findings); WCC was  $13.2 \times 10^9/\text{L}$ . The patient was reviewed the next morning by the surgical team and the consultant. On examination, the patient was peritonitic with a pain score of 7/10. It was deemed important to exclude ischaemic bowel.

A laparotomy was performed the day after admission. ICU agreed to postoperative support and an acute resuscitation plan was in place. A full adhesiolysis was not performed because ischaemia was excluded and there was a risk of further enterotomies. Postoperatively in ICU, the patient progressively deteriorated (lactate rising from 1.4 mmol/L to 7.7 mmol/L) with acidaemia, shock requiring vasopressors, abdominal pain, and WCC  $\times 10^9/\text{L}$  increasing from  $13 \times 10^9/\text{L}$  to  $22 \times 10^9/\text{L}$ . There was concern that ischaemic small bowel could still be present.

Discussions with the patient’s family presented the possible options of palliation, observation or operation. The family wanted to pursue laparotomy for prognosis and possible therapy.

A relook laparotomy full adhesiolysis was performed with anastomosis resected and end-ileostomy. The stoma was dusky but viable. Reperfusion options were discussed with vascular surgery. It was concluded that no reperfusion options existed because any approach would be technically challenging. The patient continued to deteriorate with increasing vasopressor requirements and rising lactate. The stoma remained viable but dusky. After discussions with family, palliative care commenced and the patient died 5 days postadmission.

## DISCUSSION

This was a difficult case but not an uncommon scenario: that of the treating team, the patient and the alternate decision-makers wrestling with the practically achievable aims of surgical treatment in the context of concerns about futility. Futile, or non-beneficial treatment, is not defined in law, but is often used to describe treatment that is of no benefit, cannot achieve its purpose, or is not in the best interest of the patient.

Clinicians—and their patients—decide whether treatment is futile or non-beneficial. When courts or tribunals are asked to review these matters, they almost always agree with the clinical assessments of futility, so long as clinicians have undertaken a reasonable process to reach this determination. Thus, in the absence of a definition of futility, we rely on the process to determine whether these concerns were addressed in this instance.

In this case, the records of discussion of the consent process (entered by the surgical Fellow and registrar in the electronic record for the first and second operations) clearly included a surgical plan that could reasonably achieve its purpose, suggesting the surgical plan was not futile.

For the first procedure, the surgeon’s perspective was to explore and resect a non-viable segment of bowel (achieved successfully only a few months earlier). The aim from the patient’s perspective was to return to his previous level of comfort (baseline), albeit in a high acuity nursing care facility.

For the second procedure, the surgeon was concerned that the patient had deteriorated. The surgeon’s aim was to exclude or diagnose and treat something that had been missed or had evolved or was a complication of the first procedure. The family member (alternate decision-maker) agreed with this aim because it would provide prognostic information that would aid the family’s decision to proceed to palliation/treatment, although it was unlikely to rescue the patient.

The process of communication and consent (including documentation) with the patient and relatives was excellent. The high risk of death was raised and documented for both the first and second operation. This gave the patient's alternate decision-makers opportunity to consider whether the plan was futile.

In retrospect, it is easy to see that a management plan was futile when the outcome is death, but this is more difficult to see in real time. The clinical team and relatives arrived at the decision to palliate the patient after a process that was reasonable, and where there was agreement with plans to proceed to surgery.

### CLINICAL LESSONS

The Australian Department of Health funds the Palliative Care Education and Training Collaborative online course End of Life Law for Clinicians, available from: <https://palliativecareeducation.com.au>

It is recommended that any clinician involved in decisions surrounding end-of-life care does this free online course.

## Case 13: Low-risk surgery does not equate to low-risk anaesthesia

### Vascular Surgery

#### CASE SUMMARY

A man age mid-70s presented with left-side varicose veins causing leg pain. He was dialysis-dependent and had significant ischaemic heart disease. He had had a coronary bypass in the past (no date recorded). Correspondence from the patient's cardiologist was reassuring and surgery (radiofrequency ablation and phlebectomy) went ahead.

The patient's admission was short, so the notes are sparse. Significantly, the letter from the cardiologist supporting intervention was not present, nor were any of the surgeon's preoperative records. The anaesthetist was unconcerned about the patient recording a functional activity level of 4 metabolic equivalents (2 flights of stairs). The patient was known to have AF, but a history of embolisation was not recorded. Warfarin had been withheld for 5 days prior to the operation. Congestive cardiac failure was not recorded.

During the radiofrequency ablation and phlebectomy procedures, the patient arrested and was unable to be resuscitated. The surgeon documented pulsatile flow in the veins suggesting significant tricuspid regurgitation. Immediate post-arrest blood gas analysis documented high potassium level (normal for this patient) and normal calcium despite known hyperparathyroidism. The transoesophageal echocardiogram (TOE) during CPR showed some structural cardiac disease.

The coroner elected not to undertake a postmortem.

#### DISCUSSION

This patient died suddenly under anaesthetic for uncomplicated varicose vein surgery. A death during surgery, especially relatively minor surgery, is always cause for concern. This case serves as a reminder that low-risk surgery does not necessarily translate to low-risk anaesthesia.

This case asks the question of whether the operation was sensible in such a high-risk patient. This is hard to assess without good information about the indication for surgery. For example, the surgery might be easier to justify if the patient had a venous ulcer but less justifiable for less complicated varicose veins.



Reassurance from the cardiologist was sought but proved to be optimistic. A new echocardiogram was not undertaken. It seems that this might have changed the outcome but it was not thought to be necessary. Such reassurance should always be regarded as a 'piece of the puzzle' rather than a mandate to proceed.

It appears there was no preoperative assessment by the anaesthetist. Given that the patient was referred to the cardiologist, there was probably enough concern to make preoperative anaesthetic review a sensible step. Radiofrequency ablation can be completed under local anaesthetic. Taking this path may not have prevented this death, but it is worth considering for a high-risk patient. Specifically, dialysis-dependent renal failure patients present a very high risk for anaesthesia and should always be treated with the highest level of concern and respect.

Ceasing warfarin may have been a major contributor to the death of this patient. Without knowledge of risk factors such as history of embolus or congestive cardiac failure, it is difficult to comment on whether the decision to stop the anticoagulant rather than bridge with enoxaparin or a direct-acting oral anticoagulant was reasonable. It may also have been worth considering proceeding without ceasing warfarin and treating the great saphenous vein, only reserving sclerotherapy for later treatment of varices if they remained problematic.

This case was hopefully subject to rigorous review in a mortality and morbidity meeting. It is important to have sympathy for colleagues in cases like this and note that lessons learned should strengthen and amplify practice rather than damage confidence and courage.

## CLINICAL LESSONS

This case highlights the pressure to proceed that many surgeons are placed under by patients, relatives, or even fellow doctors. Ultimately, it is the responsibility of the surgeon and the anaesthetic team to assess a patient's suitability for a proposed procedure and anaesthetic. If concerns exist, it is sensible to consider seeking an opinion from the anaesthetist prior to the day of surgery. Stopping anticoagulants in the lead-up to surgery should be carefully considered.

The lack of a clear cause of death for this patient diminishes the learning opportunity to some extent. However, a careful review of all the likely precipitating causes can be instructive. Things can go wrong even in apparently low-risk settings.

# Case 14: Delayed diagnosis of ischemic bowel in a patient with stroke-like symptoms

## General Surgery

### CASE SUMMARY

A woman in her early 80s presented to the ED with slurred speech, general weakness, pre-syncope, vomiting and abdominal pain. Comorbidities included hypertension, COPD, chronic kidney disease and recent deep venous thrombosis (on rivaroxaban). She had been on long-term amoxicillin/clavulanate potassium for 10 years for an infected femoral–femoral crossover graft repair of an abdominal aortic aneurysm.

A neurology registrar assessed her on admission for a possible stroke. No focal neurological signs were found. CT of the brain and abdomen was recommended because of the abdominal symptoms. Due to the patient's renal impairment (glomerular filtration rate 28 mL/min/1.73m<sup>2</sup>), a non-contrast CT scan was performed, which showed no acute intracranial pathology. The abdominal scan revealed a small umbilical incisional hernia and faecal loading of the colon. The surgical team noted a distended and generally tender abdomen with percussion tenderness in the left upper quadrant. The patient was stable and afebrile, despite WCC of 20.2 x 10<sup>9</sup>/L. Enemas were recommended to treat the faecal loading and further contrast imaging to exclude intestinal ischaemia if the symptoms did not resolve.

The patient developed pyrexia, worsening abdominal pain and respiratory deterioration. After a further surgical consultation, a contrast-enhanced CT revealed an ischaemic left colon. The patient was seen by a surgical Fellow, and after discussion with a surgical consultant it was decided to proceed to laparoscopy, possible laparotomy and colostomy. Discussions with the patient and her family explained the risk of surgery, considering the patient's physiological status, and consent was given to proceed.

Thirteen hours after presentation, Prothrombinex and tranexamic acid were administered and the patient was taken to theatre, where laparoscopy was performed. An ischaemic descending and sigmoid colon, adhesions and turbid fluid in the pelvis were noted. The procedure was converted to a laparotomy due to an iatrogenic injury to the proximal transverse colon during entry. The injury was repaired with sutures and an omental patch applied. A left hemicolectomy and Hartmann's procedure was then performed. The patient was transferred (still intubated) to ICU for postoperative care.

The postoperative course encompassed ongoing pyrexia, hypertension, high ventilatory requirement and persistent ileus. The patient was in severe pain despite a ropivacaine infusion via rectus sheath catheters, fentanyl boluses, IV paracetamol and IV infusions of propofol and ketamine. On postoperative day 4, a member of the acute pain service inserted an epidural catheter, despite the patient having an abnormal clotting profile (activated partial thromboplastin time [aPTT] of 59 seconds). The epidural analgesia was effective and facilitated weaning from the ventilator. The patient remained hypertensive.

Meanwhile, the surgical team was concerned about the persistent ileus. On postoperative day 5 a contrast CT scan of the abdomen revealed postsurgical changes, a small volume of fluid and fat stranding beneath both the laparotomy and colostomy wounds. There was no evidence of intestinal leak or perforation. On postoperative day 6 the patient lost limb power and reflexes. An urgent CT scan revealed a large epidural haematoma with extensive spinal cord compression. Neurosurgical opinion was sought. It was decided not to do an emergency spinal cord decompression due to high surgical risk and the likelihood of no neurological recovery.

Gastrointestinal function slowly returned but the patient was still suffering from severe neuropathic pain that was difficult to control. She had also developed partial wound dehiscence and an enteric fistula. On postoperative day 13, after consultation with her family, the patient requested palliation. She passed away 10 days later.

## DISCUSSION

This patient's confusing initial symptomatology led to a stroke call, and due to poor renal function the initial CT imaging was performed without IV contrast. These events led to an unfortunate delay in the diagnosis of ischaemic colon via contrast CT scan. By the time the patient arrived in theatre she had severe sepsis and was inotrope dependent.

The value of a laparoscopic approach is debatable for a septic patient with a history of prior abdominal surgery. The laparoscopic approach led to an injury of the proximal transverse colon. Although the injury was repaired, it was the most likely cause of the enteric fistula. Other considerations would be either resection of the injured colon just proximal to the injury and maturing as an end colostomy, or resection of the ischaemic- and iatrogenic-injured segments in a damage-control approach, with eventual colostomy formation at a subsequent relook procedure.

The decision to insert an epidural catheter for ongoing postoperative pain was reasonable, although it made weaning from the ventilator difficult and may have contributed to the patient's ongoing hypertension (despite rectus sheath

catheters and administration of multiple analgesic agents). The incidence of epidural haematoma causing paralysis is estimated to be between 1:40,000 and 1:50,000 in a similar setting. In this case, the combination of ongoing hypertension and an abnormal aPTT probably contributed to the development of a massive epidural haematoma. Had the clotting profile been checked and appropriately corrected before the epidural was performed, the complication that led to the patient's death may have been avoided.

Importantly, why did the patient have ongoing postoperative pain, pyrexia and ileus? The patient underwent a contaminated abdominal procedure to remove ischaemic bowel, so the most likely causes to be considered would have to be an intra-abdominal infection or bowel ischaemia. The pathologist's report—unavailable to the treating team at the time—described ischaemic changes to the bowel on both cut ends of the specimen. If a potential surgical cause for the abdominal pain had been found, the patient may not have required the epidural for analgesia.

## CLINICAL LESSONS

This case highlights several issues regarding the consequences of a delayed diagnosis of ischaemic bowel. Performing a laparoscopy is questionable in a septic patient with known previous abdominal surgery. Alternative sources for increased pain should be investigated, including intra-abdominal infection or intestinal ischaemia. Coagulation profiles should be checked prior to using epidural catheters for analgesia.

# Abbreviations

AF	atrial fibrillation
aPTT	activated partial thromboplastic time
CBD	common bile duct
COPD	chronic obstructive pulmonary disease
CPR	cardiopulmonary resuscitation
CT	computed tomography
CTA	computed tomography angiography
ED	emergency department
ERCP	endoscopic retrograde cholangiopancreatography
HDU	high dependency unit
IABP	intra-aortic balloon pump
ICU	intensive care unit
IPC	intermittent pneumatic compression
IV	intravenous
MET	medical emergency team
NSTEMI	non-ST-segment elevation myocardial infarction
NSQIP	National Surgical Quality Improvement Program
SCD	sequential compression device
SOMI	sternal occipital mandibular immobiliser
TOE	transoesophageal echocardiogram
TPN	total parenteral nutrition
Vascath	subclavian dialysis catheter
WCC	white cell count

# Notes

A series of horizontal dotted lines for writing notes, spanning the width of the page.

# Notes

A series of horizontal dotted lines for taking notes, consisting of 20 lines.

Royal Australasian  
College of Surgeons  
Australian and New Zealand  
Audit of Surgical Mortality  
24 King William Street  
Kent Town SA 5067

**Telephone:**

+61 8 8219 0901

**Email:**

[anzasm.racs@surgeons.org](mailto:anzasm.racs@surgeons.org)

**Website:**

[www.surgeons.org/anzasm](http://www.surgeons.org/anzasm)

