



ROYAL AUSTRALASIAN  
COLLEGE OF SURGEONS

**QASM**

Queensland Audit of Surgical Mortality



Northern Territory  
Audit  
of Surgical Mortality

# LESSONS from the AUDIT

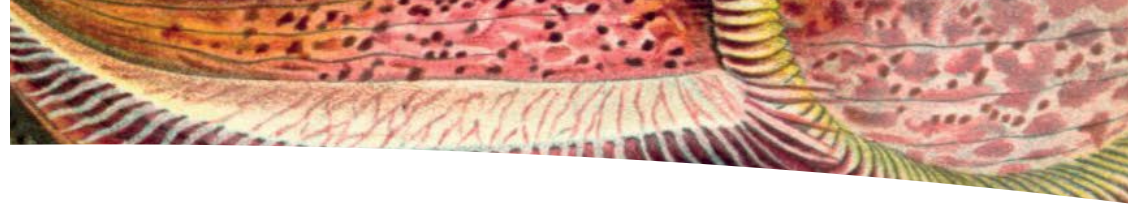
JULY 2013  
VOLUME 11



Queensland  
Government



Northern  
Territory  
Government



## Introduction

*'The single biggest problem in communication is the illusion that it has taken place.'*  
(George Bernard Shaw)

Communication is one of the core competencies of the Royal Australasian College of Surgeons (RACS) and I believe that better communication skills will ensure that surgical practice remains a profession of renown.

*Lessons from the Audit* (Volume 11) is themed '**Communication is critical**' and presents seven case studies from the Queensland Audit of Surgical Mortality (QASM). The format of Volume 11 has changed from previous *Lessons* and we trust that this will be advantageous for all readers.

QASM endeavours to play an educative role in the professional lives of Queensland surgeons and does this efficiently and effectively by providing peer-reviewed case studies from all surgical specialties.

In the past, QASM has surveyed surgeons to determine QASM's effectiveness and relevance to their surgical practice (see Appendix 1). This survey showed that 30% of those who responded said that the QASM process had triggered changes in their surgical practice.

When asked: *Which aspects of QASM helped you the most?* '*Lessons from the Audit*' was the most frequent response.

And, when asked: *How has QASM helped you change your practice?* '*Improved documentation*' was the most frequent response.


Issues relating to documenting, consenting, and communicating are specifically highlighted in this volume of *Lessons from the Audit*, and each case study carries two QASM recommendations.

I welcome your feedback on this volume of *Lessons from the Audit*.

Yours sincerely

John North  
QASM Clinical Director

Disclaimer: This booklet is produced for Fellows of the Royal Australasian College of Surgeons. Information is obtained under a quality assurance activity. Detail that may identify individuals



Cover and images used: *Art Forms in Nature; The Prints of Ernst Haeckel*.

(Colour plates reproduced from the first edition. *Kunstformen der Natur*, Leipzig and Vienna, Bibliographisches Institut 1904.)

Prestel Publishing Ltd., 4 Bloomsbury Place, London WC1A 2QA  
[www.prestel.com](http://www.prestel.com)

*Lessons from the Audit* (Volume 11) is designed and printed by Entegy ([www.entegy.com.au](http://www.entegy.com.au)); Brisbane, Australia.

This publication is available online at [www.surgeons.org/qasm](http://www.surgeons.org/qasm) (report and publications).



## Shortened forms

<b>AAA</b>	abdominal aortic aneurysm	<b>MDT</b>	multi-disciplinary team
<b>AHD</b>	advanced health directive	<b>MI</b>	myocardial infarction
<b>CABG</b>	coronary artery bypass graft	<b>NFR</b>	not for resuscitation
<b>CPR</b>	cardiopulmonary resuscitation	<b>NSTEMI</b>	non-ST elevation myocardial infarction
<b>CSF</b>	cerebrospinal fluid	<b>PET</b>	positron emission tomography
<b>CT</b>	computed tomography	<b>SAH</b>	subarachnoid haemorrhage
<b>CTA</b>	computed tomography angiography	<b>TAA</b>	thoracic aortic aneurysm
<b>CxM</b>	marginal branch of circumflex coronary artery	<b>TEVAR</b>	thoracic endovascular aneurysm repair
<b>ECG</b>	electrocardiogram		
<b>ED</b>	emergency department		
<b>EF</b>	ejection fraction		
<b>EVD</b>	external ventricular drain		
<b>FFP</b>	fresh frozen plasma		
<b>GCS</b>	Glasgow Coma Scale		
<b>GP</b>	general practitioner		
<b>HDU</b>	high dependency unit		
<b>ICA</b>	internal carotid artery		
<b>ICP</b>	intracranial pressure		
<b>ICU</b>	intensive care unit		
<b>INR</b>	international normalised ratio		

## Contents

Case study (1) Neurosurgery	3
Case study (2) Cardiothoracic	5
Case study (3) Neurosurgery	7
Case study (4) Vascular	10
Case study (5) General	13
Case study (6) Orthopaedic	16
Case study (7) Vascular	18
Appendix 1 (Surgeons' survey)	20
Further reading	22



## Case study (1) Neurosurgery

The QASM assessor specifically stated that for this case there was a “lack of discussion with the neurosurgery unit which may have altered the decision for treatment at the regional hospital”.

A summary of the case follows.

### The patient:

- was middle-aged.
- had a ventriculo-peritoneal shunt (for hydrocephalus with a history of one previous acute blockage causing coma and requiring emergency surgery).
- suffered an intraventricular haemorrhage. (Note: The haemorrhage ‘almost certainly caused the shunt to block resulting in raised intracranial pressure’).
- presented at a small regional hospital (more than one hour flight time from a neurosurgical unit).

### What happened at the small regional hospital?

- The patient was assessed, attended by a retrieval team, and sent to a tertiary referral hospital (arriving eleven hours after presenting at the small regional hospital).
- Delay in relieving the patient’s raised intracranial pressure (“secondary to consideration of the patient having an advanced health directive (AHD) which indicated that this patient was not for supportive treatment in such a scenario”).

The patient’s family “initially declined surgical treatment and consented several hours after admission”.

### What happened at the tertiary referral hospital?

- Emergency placement of ventricular drain which relieved the cerebrospinal fluid (CSF) pressure but patient remained in coma and died seven hours later.
- The patient’s family initially declined surgical treatment but consented several hours after admission.

### What issues are highlighted by this case?

- There is a changing trend in retrieval services for neurosurgery cases. In the past, it was common for every regional hospital to have an emergency craniotomy kit to enable production of a burr hole into the skull to relieve pressure. Relevant staff was trained in this procedure. With the advent of helicopter and fixed-wing transport (and presumably a medico-legal risk analysis), the desire for regional and rural hospitals to undertake these types of procedures has reduced.
- It is less than optimal care that this patient’s condition was discussed only with the retrieval team and not discussed with a receiving neurosurgery unit at a tertiary referral hospital upon presentation at the regional hospital. This represents a failure to engage specialist neurosurgery care for a patient who at

least required telephone consultation. It is possible that if given this telephone review, the regional hospital may have been willing to perform a relatively straight forward operation under the support and guidance by the neurosurgery unit (at a tertiary referral hospital).

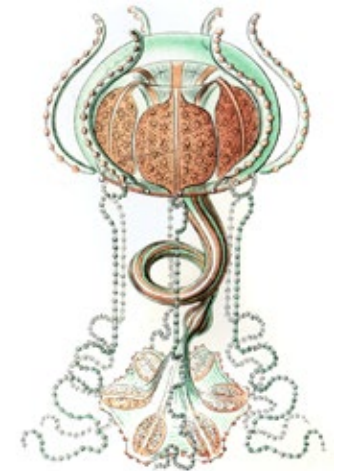- Acute treatment despite an AHD is a difficult topic to address as it brings in a number of ethical dilemmas. This family was fully engaged and they indicated that their family member would not have wished for acute treatment. They subsequently altered this decision. However, does this give the treating hospital the right to override what would seem prima facie to be good evidence of the wishes of the patient?

### QASM recommendations:

- That retrieval of a patient with a neurosurgical presentation should be discussed early with the receiving neurosurgery unit and not just the retrieval team. The QASM assessor stated: “The Neurosurgery Society of Queensland has regularly discussed this issue in its meetings and considers that retrievals of a neurosurgery nature should be discussed with the receiving neurosurgery unit and not just the retrieval team. This approach would be consistent with the practice in most major hospitals so a patient who presents there, where the receiving unit (usually the Emergency Department)

liaises early and closely with the specialist neurosurgery unit.”

- Discussion about AHDs should be undertaken early and with all parties involved. Any questions or concerns about the AHD should be discussed with the family and, if necessary, the adult guardian.





## Case study (2) Cardiothoracic

The QASM assessor specifically stated that “this patient had a high risk of dying during re-do surgery. Using several models, it was certainly approaching a 50 per cent risk of dying. There were no records in the notes that these issues were ever discussed with the patient”.

A summary of the case follows.

### The patient:

- was elderly.
- had previous coronary surgery over 15 years ago.
- had co-morbidities (hypertension, hypercholesterolaemia, peripheral vascular disease, smoker).
- had impairment with activities of daily living.
- was admitted to hospital with chest pain characteristic of angina.

### What happened at hospital? (pre-operative management)

- The patient’s cardiac enzymes suggested a NSTEMI.
- The patient’s chest pain settled promptly with treatment.
- CT angiogram showed a patent mammary artery graft from previous surgery and extensive calcification of remaining coronary vessels (and

moderate to severe centrilobular emphysema with extensive apical scarring and right lower lobe atelectasis).

- Coronary angiogram showed normal left ventricular function, a patent mammary graft, significant calcific stenosis in the left main and circumflex systems, and mild disease in the right coronary artery.

### What happened at hospital? (post-operative care)

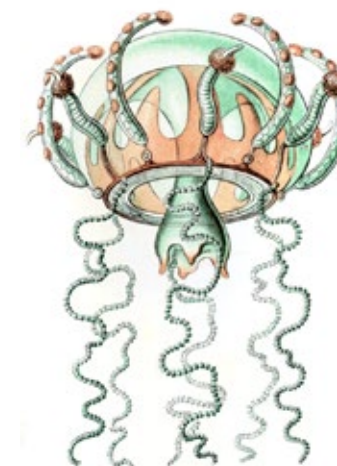- The patient remained pain-free and mobilising until the time of surgery.
- Surgery was a Coronary Artery Bypass Graft (CABG) with a left radial artery placed to the CxM (marginal branch of circumflex coronary artery).
- The patient suffered a severe post-operative bleed requiring re-operation.
- The bleeding was difficult to control as it appeared to be coming from the lateral surface of the heart and needed re-institution of bypass.
- The patient became unstable requiring large volumes of blood products and inotropic support to wean from bypass.
- Echocardiography showed impairment of left ventricular function due to perioperative infarction.
- The patient had respiratory failure, cardiac failure, severe diarrhoea, and died of multi-organ failure several weeks after surgery.

### What issues are highlighted by this case?

- Using several models, one assessor’s view was that this patient’s risk of dying during re-do surgery was certainly approaching 50%.
- For this high-mortality-risk re-do surgical patient, there were no notes in the medical record to suggest that this high risk of dying was discussed with the patient. The generic ‘informed consent’ form at the time mentioned ‘5% risk of dying’ with an opportunity to modify but this was never done.
- Based on the clinical documentation, it cannot be established whether or not the patient was fully informed of the high risk of dying in this particular case and, if not, whether he/she may have decided against surgery had he/she known the real risks.

### QASM recommendations:

- All surgeons using Department of Health consent forms ensure they use the most current form from the website and carefully consider adopting or amending the information for each individual patient.
- Regardless of which format is used for documentation of consent, all surgeons should ensure that the risks and benefits of surgery are thoroughly discussed with the patient and the discussion adequately documented.





## Case study (3) Neurosurgery

The QASM assessor specifically stated “it is not clear from the clinical record whether the staff in hospital A were aware that at the time of the subarachnoid haemorrhage, she was pregnant. There is no indication of that in the progress notes which seem incomplete for this admission or in the referral letter to hospital B.”

A summary of the case follows.

### The patient:

- was under 40 years and pregnant.
- had a history of hypertension and non-compliance with medication.

### What happened at hospital A?

- The patient presented at hospital A (day one) with sudden onset headaches.
- Examination revealed GCS 15 and no focal neurological signs (GCS decreased to 13 and then to 10).
- Blood pressure was raised (systolic levels 210-230 mmHg).
- Thiopentone and fentanyl were given with intubation.
- Day two, a CT scan and a CT cerebral angiogram were performed (revealing subarachnoid blood in the pre-pontine and basal cisterns; and a very small infundibulum arising from the right distal internal carotid artery – there was blood in this region around the proximal middle cerebral artery (first part). Scan and

angiogram had shown some dilatation of the lateral ventricles consistent with hydrocephalus. There was a large volume of subarachnoid haemorrhage.)

- The radiologist concluded “no aneurysm or cause of the acute subarachnoid haemorrhage is demonstrated”. A qualifying comment: “There is a known incidence of false negative interpretation in acute subarachnoid haemorrhage. Follow-up angiography is suggested at an appropriate time”.
- It was not clear if the staff knew the patient was pregnant. There is no indication in the progress notes (seemingly incomplete for this admission) and no indication in the referral letter to hospital B.
- The patient was transferred to hospital B after nimodipine infusion and phenytoin loading.

### What happened at hospital B?

- The patient was admitted to hospital B, one day after admission to hospital A (day two).
- The patient was intubated and sedated.
- Obstetric ultrasound indicated 20 weeks pregnancy.
- Foetal compromise was present and non-survival likely.
- Nimodipine was continued and ECG indicated cardiac stress.
- Blood pressure was under control.

- It is not clear whether a further angiogram was performed (clinical record states “CTA awaiting recon”. Some of the neurosurgical entries in the progress notes are illegible. One entry states that a review of the CTA showed a possible ICA or basilar tip aneurysm.
- Notes suggest patient was scheduled for the operating theatre for insertion of an external ventricular drain (lack of access prevented this because of multiple cases in the afternoon and the evening).
- The patient was transferred to hospital C.

### What happened at hospital C?

- The patient was admitted to hospital C, still day two at 2300hrs (subarachnoid haemorrhage grade 3).
- Arrangements were made to insert an external ventricular drain, to be performed by the neurosurgical registrar.
- The obstetrics and gynaecology team assessed the patient who was unlikely to deliver a viable foetus.
- Day three (after admission to hospital A), review of radiology and angiogram revealed that the aneurysm identified on the internal carotid artery was not suitable for coiling. The decision was made to proceed with an open operation. (The QASM assessor could not confirm whether an external ventricular drain was performed as a separate procedure. Also, there is no record in the operation report that the lateral ventricle was punctured

“although there are entries in the clinical record for the post-operative period where ICP was measured using an EVD. It seems probable that the ventricular drain was inserted at the time of definitive clipping of the right internal carotid aneurysm.”)

- With the consultant surgeon operating and the registrar assisting, a right frontotemporal craniotomy was performed. A standard craniotomy was performed, a Sylvian fissure split to identify the proximal middle cerebral artery (first part) segment and carotid bifurcation was carried out. There was a blister like aneurysm, definite source of the SAH on the anterolateral ICA wall and this was clipped. There was also a posteromedial component of the aneurysm sac which was partially clipped but at this point, the blister portion of the aneurysm ruptured and required multiple attempts with three episodes of temporary clipping of the carotid artery, the anterior cerebral artery (first part) and the middle cerebral artery (first part). “The conditions were difficult as it sounded as though there was considerable clot and fibrin around the aneurysms.”
- Post-operatively, the external ventricular drain was left on free of drainage at 15cm and the patient was returned to the ICU for ventilation and sedation. The patient’s condition remained poor but blood pressure well controlled. The external ventricular drain remained patent.



- Day seven, an emergency removal of placenta was performed. The foetus was non-viable.
- The patient’s intracranial pressure rose and stabilised at 35-40 mmHg (N=<10mmHg).
- Day nine, the patient’s critical condition did not improve and the patient died (following cardiac arrest).

### What issues are highlighted by this case?

- The importance of a more comprehensive discussion of treatment plans, for cases such as these, at hospital A.
- Some of the handwriting in the medical records at hospital B was illegible and some of the content was incomplete.
- The provision of a state-wide image transfer service is highly desirable where CT cerebral angiography is performed in smaller hospitals without a neuroradiologist in attendance. Consultations can then be performed and experienced opinion provided to smaller hospitals.
- There was a major delay in the insertion of an external ventricular drain in hospital B.

### QASM recommendations:

- That retrieval of a patient with a neurosurgical presentation should be discussed early with the receiving neurosurgery unit and not just the retrieval team.

- For all consultant surgeons, the Department of Health should ensure access to and transfer of all digital images between all hospitals.



### Case study (4) Vascular

The QASM assessor specifically stated for this case that “it is understandable that there may have been some conflict concerning the decision to operate; as far as a formal process is required in such situations, I suspect that the best approach is non-emotional, sensible and rational discussion between relevant consultants to come to a collective decision.”

A summary of the case follows.

#### The patient:

- was elderly.
- was admitted medically to a metropolitan hospital.
- had multiple co-morbidities:
  - › ischaemic heart disease with previous coronary artery bypass graft (CABG) over 20 years ago after two myocardial infarctions;
  - › on warfarin for atrial fibrillation;
  - › congestive heart failure with ejection fraction (EF) 34%;
  - › metastatic prostatic cancer;
  - › chronic renal failure; and
  - › peripheral vascular disease (three right toes previously amputated).

#### What happened at the metropolitan hospital?

- The patient was admitted medically for general deterioration, poor mobility, dehydration, and swallowing problems.

- **Five days post-admission:**  
The patient fell on the toilet floor and suffered multiple skin tears to toes and legs. (It was unclear from the medical records reviewed by the QASM assessor whether the fall was preventable). The patient remained under the care of the medical team – investigations showed liver cirrhosis and ascites with multiple bony metastases.
- **Seven days post-admission:**  
The toe wound was cleaned and noted to be cellulitic, swollen, and oozing serosanguinous fluid. The patient started on oral Dicloxacillin.
- **Nine days post-admission:**  
Cellulitis and tenderness increased. The patient developed an acute confusional state; chest x-ray had noted an area of consolidation at the right base; patient started on intravenous Clindamycin and oral Cefuroxime.
- **Ten days post-admission:**  
The patient’s right foot was very swollen with dark purple patches and sluggish capillary refill – palpable dorsalis pedis pulse was documented.  
  
**Surgical review:**  
Discussion with the patient’s family included: a *not for resuscitation* (NFR) decision and options including amputation – conservative treatment rather than to amputate.

The medical team were advised by the surgical team to manage the patient conservatively. The patient’s forefoot



was cold, purple, dusky, and painful with no palpable pulses in the right foot.

- **Eleven days post-admission:**

The patient was pain free and the right foot was unchanged. The patient was becoming more lucid and apparently understood all health-related issues. The patient consented to have the leg amputated.

Subsequent anaesthetic opinion was sought; significant co-morbidities were noted; the patient drifting in and out of lucidness was noted. When lucid, the patient definitely wanted the operation. Therefore, a decision to amputate was undertaken.

The patient's INR = 4.9 plus four bags of fresh frozen plasma (FFP) were given. Later that day INR = 2.1 and no further FFP was given.

The ICU consultation noted the patient wanted amputation but was not for 'advanced life support'. In the case of clinical deterioration, comfort measures only were to be provided. The family agreed.

- **Twelve days post-admission (morning):**

The patient was disoriented in time and place, and not remembering surgery was due. (INR = 2.5 and two units of FFP were given)

- **Twelve days post-admission (afternoon):**

The anaesthetic consultation noted theatre time was unable to accommodate the patient earlier and

that the patient was combative and unwilling for blood to be taken.

The patient proceeded to surgery for a right above knee amputation with minimal blood loss. (INR = 1.9).

- **Thirteen days post-admission (post-operation):**

The patient was stable the day after the operation but then gradually deteriorated (hypotension, decreased consciousness, reduce urine output, remained hypotensive but no fluid overload). The patient had continuing 12<sup>th</sup> hourly fluids. At 11:00, the patient was noted to be found by the nursing staff with the oxygen mask pulled off and no signs of life

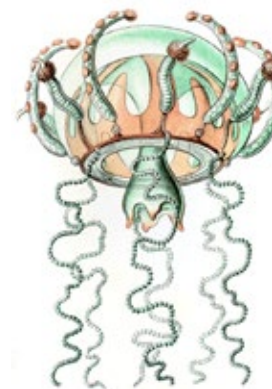### What issues are highlighted by this case?

- Clinical management of elderly patients with co-morbidities is difficult.
- Vascular reconstruction is rarely indicated. Conservative approach eventually leads to death or amputation results in a poor quality of life.
- The decision to operate was well documented. However, the issue of competence is a difficult one. Was the patient competent to consent?
- The patient, on admission, was high risk for falls. Active measures were implemented to prevent falls except for bed rails.
- Early surgical consultation should have been sought.

- Suturing of wound on a leg with signs of peripheral ischaemia was not the most appropriate course.
- Intravenous antibiotics were delayed.
- Surgical consultation was delayed.
- INR needed to be reversed and perhaps could have been performed more efficiently with use of Prothrombinex.
- There was some conflict concerning the decision to operate.

### QASM recommendations:

- Surgeons need to be well informed about 'very ill' patients and the legitimacy of their consent.
- Surgeons need to consider, in all cases, the competency and capacity of the patient they are consenting.







## Case study (5) General

The QASM assessor specifically stated that “on admission there seemed to be a demarcation dispute whereby the subspecialty unit refused admission, nominating the acute surgical unit as being responsible while the patient was awaiting a PET scan.”

A summary of the case follows.

### The patient:

- was middle-aged.
- was transferred from a regional hospital to a tertiary referral hospital.
- had co-morbidities: obesity and obstructive sleep apnoea.
- had laparoscopic adjustable gastric banding (2005) with initial weight of 200 kilograms. Initial weight loss was 50 kilograms with a further 40 kilograms six months later including a significant deterioration in swallowing. At that time, the patient had an upper endoscopy in a regional hospital. (Findings indicated a locally advanced distal oesophageal tumour.) The patient was then to attend a tertiary referral hospital for review at a multi-disciplinary team (MDT) clinic.

Note: The referral had been made by the treating surgeon at the regional hospital who discussed the patient with the director of the subspecialty unit.

Note: Medical notes state that the patient had been advised (by the general

practitioner) to stop anti-hypertensive medication around the time of the referral.

- En route to the tertiary referral hospital, the patient had significant headache and left arm pain so attended a different regional hospital. CT brain scan was negative and the patient was noted to be significantly hypertensive.
- The patient was discharged and continued to the tertiary referral hospital.

### What happened at the tertiary referral hospital?

- The patient was admitted to the acute surgical unit with significant hypertension.
- While the patient was awaiting a PET CT scan, a subspecialty unit refused admission nominating the acute surgical unit as responsible.
- **One day post-admission:**  
The patient was seen by the subspecialty unit and a plan was made for discussion at the MDT meeting the following day.
- **Two days post-admission:**  
The patient had a whole body CT PET scan and complained of chest pain (the acute surgical unit intern attended). An ECG did not show any acute ischaemic changes.

A topical nitrate patch was placed which lowered the patient’s blood pressure but the blood pressure rose the following evening. Patient remained unwell with headaches.

- **Three days post-admission:**  
A trial of oral medication to control blood pressure was started. Consent for an upper endoscopy was dealt with by the intern. This consent details the significant risks as handwritten by the intern of an upper endoscopy being “defecation problems, faecal impaction and damage to anus, bowel and rectum”.

The patient was prescribed a once-daily dose of 5000units of heparin subcutaneously. This would not be an acceptable thromboprophylactic dose for a 100kg patient with a known malignancy.

- The patient still complained of a significant headache (systolic blood pressure 185mmHg) and underwent an upper endoscopy.
- The post-procedure observation chart shows a blood pressure variously recorded at 198/116mmHg to a maximum of 218/114mmHg. During this time, the patient continued to complain of a significant headache with a pain score of 7/10.
- **Four days post-admission:**  
Patient found collapsed in the ward and a cardiac arrest was called. (246mmHg/160mmHg with a pulse rate of 109 beats per minute)  
  
Intubation was attempted with escalating difficulties to an attempted cricoid puncture which failed and marked acute pulmonary oedema.

The patient was eventually intubated by the Director of Intensive Care.

The patient was not transferred to ICU because of the PET scan findings alluded to in the medical records (but not documented) suggesting metastatic malignancy.

Treatment was withdrawn after discussion between all involved consultants with no family nearby. The family was subsequently informed. This would have been a challenging outcome and process for the family.

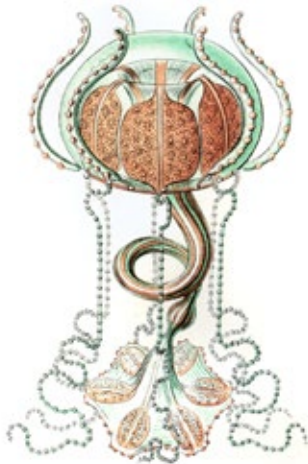### What issues are highlighted by this case?

- The progressive significant hypertension with prior documented withdrawal of medication, culminating in progressive headache, left arm and chest pain without myocardial ischemia on ECG or biochemically. Timely attention to control of the severe hypertension would have seemed appropriate especially in retrospect.
- The lack of familiarity with the consultation procedure of upper endoscopy by an intern in a subspecialty unit where this procedure was performed.
- The appropriateness of the QASM surgical case form being completed by a ‘basic surgical trainee’ instead of the consulting surgeon.



### QASM recommendations:

- Surgical interns must understand the importance of accuracy in the explanation given when obtaining informed consent, and consultant surgeons must be aware of the competency level of interns before delegating critical tasks.
- QASM surgical case forms are to be completed, where possible, by the consultant surgeon. Where this is not possible and the consultant surgeon delegates this task to a surgical intern, it is the consultant surgeon's responsibility to review the content of the QASM surgical case form before submitting it to QASM.



### Case study (6) Orthopaedic

The QASM assessor specifically stated that for this case "it would seemingly appear that there were deficiencies not only in the initial assessment in the Emergency Department and Intensive Care Unit and communication between the two teams but also within the Orthopaedic Department itself."

A summary of the case follows.

#### The patient:

- was elderly.
- was admitted to a metropolitan hospital with chest pain and left shoulder pain.
- had comorbidities including Crohn's disease (on long term steroids).

#### What happened in the hospital?

- The patient was triaged in the emergency department (ED).
- The patient was not seen by the medical staff until the patient had a grand mal seizure four hours post-admission.

#### What happened in the emergency department?

- A nurse categorised the case but there is no documentation of the review time.
- The medical registrar recorded the swollen left shoulder.
- The patient was unable to move after the grand mal seizure but this was poorly documented

- The ED consultant requested orthopaedic review for the patient after the grand mal seizure.
- The Orthopaedic registrar examined the patient and ordered an x-ray of left shoulder. The results were poorly interpreted and the pathology was not recognised.
- The ED consultant reviewed the patient who was thought to be septic. The patient was transferred to ICU for respiratory support.

#### What happened in the intensive care unit?

- The left shoulder joint was aspirated and revealed a haemarthrosis suggesting trauma.
- Ventilation continued.
- The registrar notes some swelling in the right shoulder, not previously noted by the orthopaedic team.
- Day 4 in ICU – the Orthopaedic consultant ward round confirms pathology probably in both shoulders (perhaps as a consequence of the seizure) and CT requested of both shoulders.
- Septicaemia continued despite no growth from aspirate from left and right shoulders.
- No clear cause for septicaemia or seizures was discovered. The patient passed away four weeks after admission.



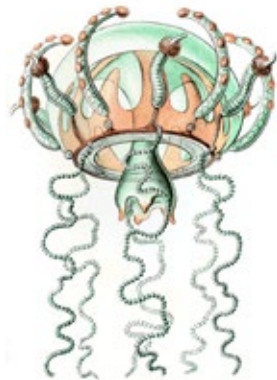- Cause of death was multi-organ failure as a consequence of septicaemia.

### What issues are highlighted by this case?

- The ED made an inadequate assessment and diagnosis. Despite being in ED for several hours, it was not until the patient had a grand mal seizure that appropriate assessment took place. The seizure appears to have been as a consequence of a septicaemic episode the patient was suffering.
- Documentation in the ED lacked quality and the collateral history from the spouse was imprecise. The cause of the septicaemia does not seem to have been identified but could have been related to unrecognised septic arthritis in the left shoulder.
- Not only was there poor communication within ED but this extrapolated to ICU, and then from ICU to the Orthopaedic team.
- This patient should have been seen by the Orthopaedic consultant soon after admission to ICU for appropriate 'work-up'.
- The patient passed away after several weeks in intensive care despite appropriate investigations. These investigations were delayed and the responsible team was slow to respond.

### QASM recommendations:

- Hospital and Health Services should ensure adequate staffing in emergency departments to appropriately assess patients in a timely manner.
- Quality documented assessment should/will lead to early diagnosis and accurate diagnosis.



### Case study (7) Vascular

The QASM assessor specifically stated that there was 'lack of communication between the vascular surgeons at hospital (1) and hospital (2)' and that there was 'possible misdiagnosis by the surgical trainee at hospital (2)'.

A summary of the case follows.

#### The patient:

- was elderly.
- had comorbidities: ex-smoker, hypertension, elevated cholesterol, atrial fibrillation (on warfarin).
- had (15 years previously) an abdominal aortic aneurysm (AAA) repair at hospital (2).
- was admitted to hospital (1) with chest pain and nausea. The assessor felt that "it was not obvious in the outpatient department that the patient had a ruptured aneurysm".

#### What happened at hospital (1)?

- The patient was being worked up for a thoracic endoluminal stent graft at hospital (2) but wanted to change care to hospital (1) for logistical reasons.
- A discussion took place with the surgeon at hospital (1) that no stents were available in hospital (1) at that time, and that if there was any problem with

the aneurysm the patient would have to go back to hospital (2). The patient accepted this scenario.

- An urgent CT in hospital (1)'s ED followed this discussion.
- The CT revealed further enlargement of the aneurysm, with intramural haematoma (suggesting rupture), plus a new dissection.
- This was communicated to the vascular surgeon at hospital (1) who told the ED at hospital (1) to send the patient to hospital (2) because the patient had been on the waiting list to have a TEVAR (Thoracic Endovascular Aneurysm Repair) at hospital (2) and there was no facility to perform TEVAR at hospital (1).
- The ED consultant at hospital (1) informed the vascular surgical trainee at hospital (2) about the patient. It is unclear from the medical records if the vascular consultant surgeon at hospital (2) saw the CT.
- The patient was then transferred to hospital (2).

#### What happened at hospital (2)?

- The patient arrived at hospital (2) normotensive and alert.
- The initial assessment by the vascular surgical trainee was that the patient had an aortic dissection.
- The patient was transferred to HDU for blood pressure control.



- One hour later the patient arrested; CPR was performed, but stopped because there was no benefit, given the aortic pathology.

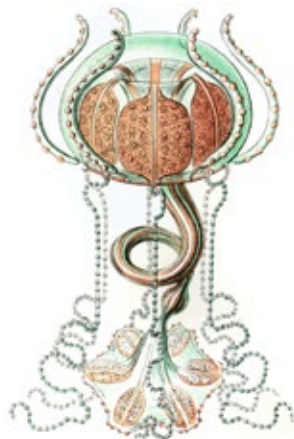### What issues are highlighted by this case?

- The need for direct communication between the vascular surgeons at hospital (1) and hospital (2). After review of the imaging, the patient may indeed have been deemed inoperable and not transferred. If the aneurysm was operable, hospital (2) may have been better prepared to accept the patient directly into the endovascular suite potentially saving the patient's life.
- It was unclear to the QASM assessor whether these two hospitals shared an imaging system. Potentially the receiving team at hospital (2) could have reviewed the images as soon as they were called and ordered a stent-graft 'ready to go' (if one was not in stock).
- The diagnosis of ruptured aneurysm was never made at hospital (2).
- At hospital (1), the suspicion of ruptured TAA was clearly documented but the vascular surgical trainee at hospital (2) did not mention this and diagnosed a Type B dissection only.
- At hospital (2), there was no mention of palliation just that management appropriate for a dissection (BP control) was being commenced and the patient was not having an operation.

- Without the imaging to review, it is impossible to say which diagnosis was correct.
- In hindsight, it appears that the more likely diagnosis was that of rupture (because this is more likely to lead to sudden death). Type B dissection has a relatively low mortality rate and can be treated medically.

### QASM recommendations:

- For all consultant surgeons, the Department of Health should ensure access to and transfer of all digital images between all hospitals.
- Communication protocol must always be consultant surgeon to consultant surgeon and must always take place within critical timeframes.



## Appendix 1 (Surgeons' survey)

QASM conducted a survey of Queensland surgeons to determine the effectiveness and relevance of QASM to their work. The most salient point to come out of the survey was that 30% of those who responded said that the QASM process had triggered changes in their practice.

The results were:

- 13% (85/665) of participating surgeons responded to the survey (This is a normal response rate for this type of questionnaire.)
- 93% of those who responded said the QASM publications were informative
- 87% said QASM feedback was informative
- 65% said the QASM process has helped them to review their surgical practice
- 30% said the QASM process had helped them to change their practice

A summary of answers to survey questions is highlighted below. Surgeons were asked:

### How has QASM helped you change your practice?

- The most frequent theme of responses: improved documentation

### Which aspects of QASM have helped you the most?

- Most frequent theme of responses: *Lessons from the Audit* (case study booklet)
- Second most frequent theme of responses: feedback to surgeons

### How can QASM better serve you?

- There was a variety of responses, with the most frequent response being: *can't serve me better.*

Sample comments:

- *You are doing a good job*
- *We need to make the findings as educational as possible*
- *The QASM process is too distant from the clinical interface to be of any real benefit to the clinician i.e. anyone can review a chart & make an opinion - not usually a useful or correct one*
- *Statistics - death rate / procedure*

### Suggestions for seminars:

- 50% (41/85) of the responding surgeons said they were interested in a seminar.
- Themes of interest were: (some surgeons ticked more than one box)
  1. delay in diagnosis (23 requests)
  2. deteriorating patient (22 requests)
  3. pre-operative management (21 requests)
  4. Fluid balance / resuscitation (15 requests)
  5. Delay in transfer (14 requests)

### How has QASM helped you change your practice?

- Sample comments (by category) are listed below:
  - Documentation
    - › *Reinforced importance of written records that could explain clinical course retrospectively*



- › *Must document the reasons for a decision*
  - › *More documentation by Consultant for all cases, especially on decisions regarding high mortality risk patients*
  - › *More aware of notes and recording all events etc*
  - › *Monitoring of events and learning from others*
  - › *Importance of documentation. Every time I see patient document something*
  - › *Emphasis on documentation and record keeping. Early identification of high-risk patients allow early/pre-op intervention*
  - › *Being more diligent with recording*
  - › *Accurate recording of patient and family discussions*
  - › *(1) Documentation of co-morbidities, physical findings and decisions is improving. (2) Closer supervision of staff duties. (3) Increase in likelihood of consultation*
- Self-reflection
- › *There but for the grace of God*
  - › *Maintains an interest in sharpening clinical acumen*
  - › *Have learnt from other's complications (and own)*
  - › *Better to learn from the events of others than to experience all event 1st hand yourself*
  - › *Being more bold in decision-making - thoughtful*

#### Leadership

- › *Renewed focus on decision-making at a senior level. Each review seems to find at least a few cases where a poorly supported junior makes decisions with bad outcomes*
- › *Made me more likely to intervene with registrars under performance*
- › *Addition of higher element of peer review and advisory perspective*

#### Transfers

- › *I won't transfer dying patients!*
- › *Points out (among other things) the danger of transfer of patient and of care*

#### General


- › *In multiple ways*
- › *DVT prophylaxis - colorectal cancer patients going home on 4-6 weeks treatment*
- › *Allows one to be more prevention orientated*

#### Other/Not relevant

- › *Retire - I jest but I have reached consulting-only age*
- › *Not relevant to my current role*
- › *Never had a QASM*
- › *Mine is a limited practice - simple procedures - non-renal vascular access*
- › *I have stopped operative practice*

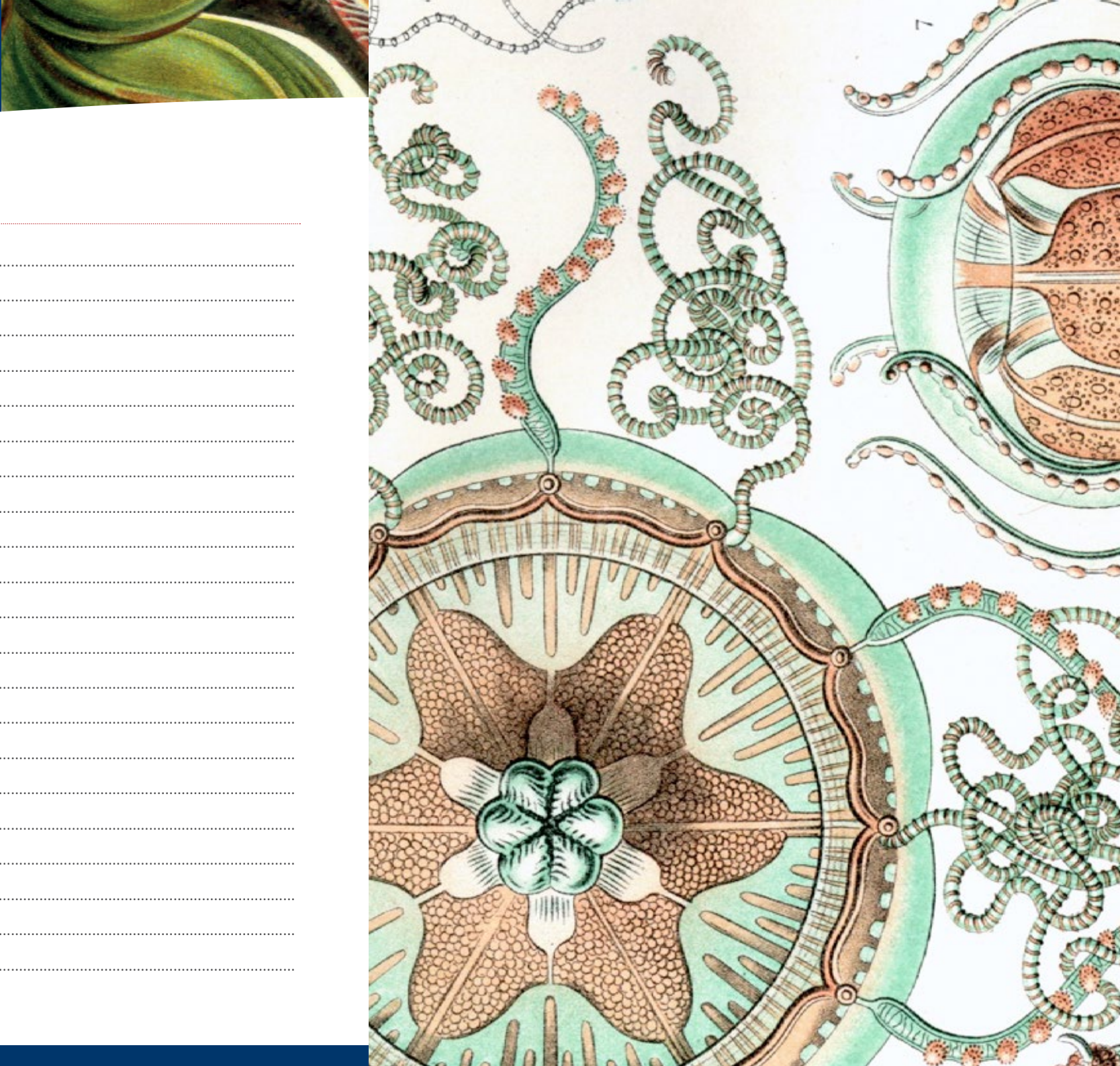
#### Further reading:

1. Sessums LL, Zembrzuska H, Jackson JL. Does this patient have medical decision-making capacity? *JAMA*. Jul 27 2011;306(4):420-427.
2. Nagpal K, Vats A, Lamb B, et al. Information transfer and communication in surgery: a systematic review. *Ann Surg*. Aug 2010;252(2):225-239.



## Notes

A series of horizontal dotted lines for taking notes.





ROYAL AUSTRALASIAN  
COLLEGE OF SURGEONS



Northern  
Territory  
Government

**QASM**

Queensland Audit of Surgical Mortality



Telephone: 07 3249 2971

Facsimile: 07 3391 7915

Email: [qasm@surgeons.org](mailto:qasm@surgeons.org)

Post: PO Box 7476  
East Brisbane QLD 4169

Web: [www.surgeons.org/qasm](http://www.surgeons.org/qasm)

Telephone: 07 3249 2973

Facsimile: 07 3391 7915

Email: [ntasm@surgeons.org](mailto:ntasm@surgeons.org)

Post: PO Box 7385  
East Brisbane QLD 4169

Web: [www.surgeons.org/ntasm](http://www.surgeons.org/ntasm)